

Combined vacuum-assisted closure treatment with laparoscopic mobilization of an omental flap and meshed skin grafts for reconstruction of infected sternotomy wounds: two cases

Veir, Zoran; Smuđ, Sanda; Bogdanić, Branko; Cvjetičanin, Bruno; Bagatin, Dinko; Dujmović, Anto; Duduković, Mladen; Ivrlač, Radojko; Bulić, Krešimir; Mijatović, Davor

Source / Izvornik: *Collegium Antropologicum*, 2009, 33, 1427 - 1430

Journal article, Published version

Rad u časopisu, Objavljena verzija rada (izdavačev PDF)

Permanent link / Trajna poveznica: <https://um.nsk.hr/um:nbn:hr:105:233095>

Rights / Prava: [In copyright](#)/[Zaštićeno autorskim pravom](#).

Download date / Datum preuzimanja: **2024-06-24**



Repository / Repozitorij:

[Dr Med - University of Zagreb School of Medicine Digital Repository](#)



Combined Vacuum-Assisted Closure Treatment with Laparoscopic Mobilization of an Omental Flap and Meshed Skin Grafts for Reconstruction of Infected Sternotomy Wounds: Two Cases

Zoran Veir, Sanda Smuđ, Branko Bogdanić, Bruno Cvjetičanin, Dinko Bagatin, Anto Dujmović, Mladen Duduković, Radojko Ivrlač, Krešimir Bulić and Davor Mijatović

Department of Plastic Surgery, University Hospital Center Zagreb, Zagreb, Croatia

ABSTRACT

In cardiac surgery, poststernotomy wounds are life threatening complications, with mortality up to 50%. We described two patients, who underwent coronary artery bypass grafting and postoperatively developed a deep sternal wound infection. Reconstruction was combined with vacuum-assisted closure treatment, laparoscopic mobilization of an omental flap and split thickness skin grafts. The omental flap is a well-vascularized local flap with a large surface area and has excellent immunologic and angiogenic properties. Both patients recovered completely. In our opinion, vacuum-assisted closure treatment and laparoscopic mobilization of great omentum is suitable option for treating deep sternal wounds.

Key words: sternal defects, vacuum-assisted closure treatment (VAC), omental flap, postoperative care

Introduction

In 1887 median sternotomy was first introduced by Milton and is considered to be the most usually performed incision in cardiac surgery, but the medial sternotomy was not popularized until 60 years later by Julian and his colleagues. However, many problems occur in poststernotomy wounds like sternal dehiscence and mediastinitis. These wounds are life threatening, with the mortality between 5% and 50%^{1,2}.

The Center for Disease Control and Prevention in the USA defined mediastinitis according to these guidelines:

1. an organism isolated from culture of mediastinal tissue or fluids;
2. evidence of mediastinitis seen during operation;
3. one of the following conditions: chest pain, sternal instability, or fever (>38 °C), in combination with either purulent discharge from mediastinum or an organism isolated from blood culture or culture of mediastinal drainage.

Diagnose of mediastinitis requires at least one of those grounds listed above³.

Incidence of mediastinitis for operations requiring a median sternotomy is 1% to 3%, with a recurrence rate of 5% to 20%. There are many risk factors for developing mediastinitis such as obesity, diabetes mellitus, chronic obstructive pulmonary disorder, heart failure, use of internal thoracic artery grafts, advanced age, female sex, active smoking, the use of steroids, atherosclerosis and preoperative hospital stay longer than 5 days²⁻⁴.

Gram-negative and Gram-positive bacteria as well as fungi are pathogens involved in sternal wound infection. Bacteria from normal skin flora, *Staphylococcus epidermidis* and *Staphylococcus aureus* are the most common organisms to be isolated from sternal wounds⁴.

The first laparoscopic harvest of omentum was performed in 1993, by Saltz and his co-workers. They used omentum as a free flap to cover a large soft tissue defect. The omental flap is a well-vascularized local flap with a large surface area (300–1500 square centimeters). Its immunologic and angiogenic properties are excellent for restricting infection in different types of tissue (extremities, heart, spinal cord, brain)^{2,5-7}.

Patient Report

During the 2008, we operated two patients who both underwent coronary artery bypass grafting (CAGB) and postoperatively developed a sternal wound infection.

First patient was a 56-year old male that had underwent a triple CAGB. On the 25th postoperative day developed a sternal wound infection. *Enterococcus faecalis* and coagulasa negative *Staphylococcus* were isolated. Patient was treated with long-term antibiotic therapy (Vancomycin 2×1 gr) combined with wound debridement and vacuum-assisted closure treatment (VAC therapy) (Figure 1). His medical history included ischemic heart disease. After the wound sample was negative on bacteria, patient was scheduled for further debridement and it was decided to use an omental flap, obtained laparoscopically, to reconstruct the thoracic wound (Figure 2).

The second patient was a 66-year old male that had underwent a double CAGB. On the 6th postoperative day he developed a sternal wound infection. Methicillin-resistant *Staphylococcus aureus* (MRSA) was isolated and

patient was treated with long-term antibiotic therapy (Vancomycin 2×1 gr) combined with wound debridement and VAC therapy. His medical history included ischemic heart disease, lung tuberculosis, diabetes mellitus, high blood pressure, hyperlipoproteinaemia, prostrate adenoma. One month later a wound sample was negative and it was decided to use an omental flap, obtained laparoscopically, to reconstruct the thoracic wound.

Indications for an omental flap were chronic infection, resulting in dehiscence of the sternotomy with advanced osteomyelitis, mediastinitis, large abscess cavities and no prior abdominal operations.

Omental flap transposition was used as the primary reconstruction. The pedicled omentum flap was based on the right gastroepiploic artery harvested laparoscopically and covered with a split-thickness skin graft (Figure 3). There were no intraoperative complications.

Postoperatively, patients were transferred to the intensive care unit (ICU) and had an average ICU stay of 10 days. The average length of stay following omental re-

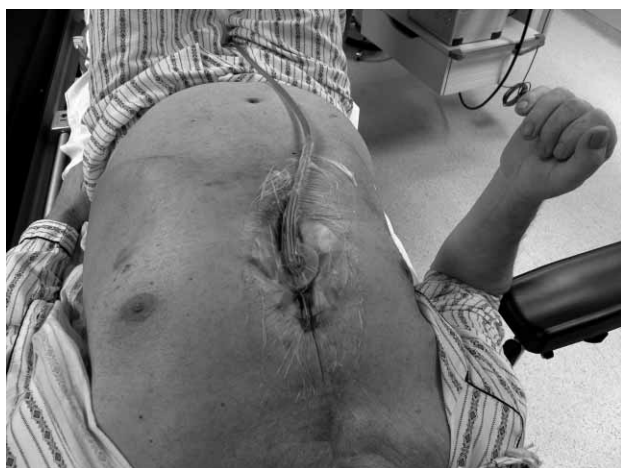

Fig. 1. Patient after sternotomy and VAC application.

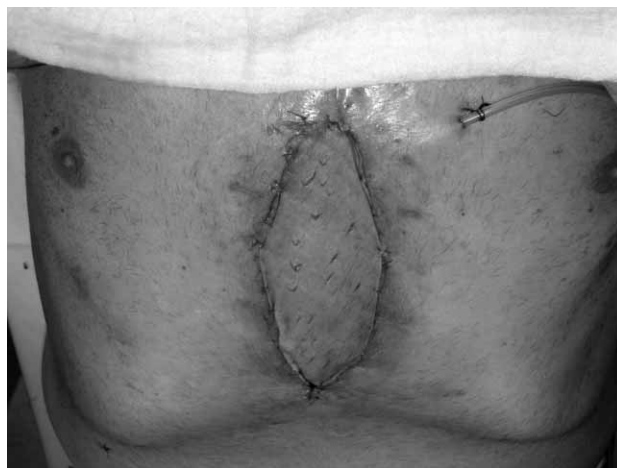


Fig. 3. Omental flap covered with split-thickness skin graft.

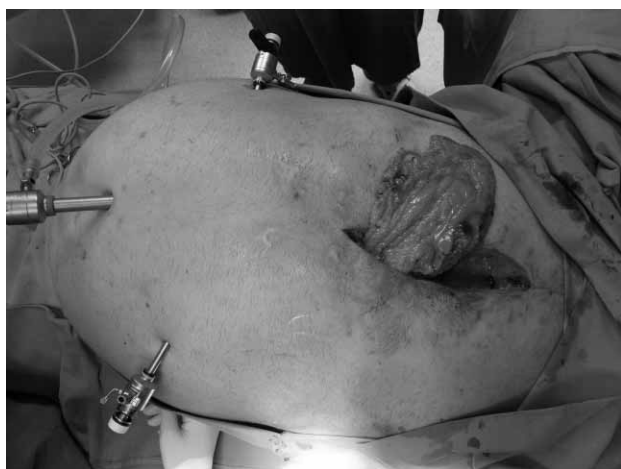

Fig. 2. Reposition of omental flap.

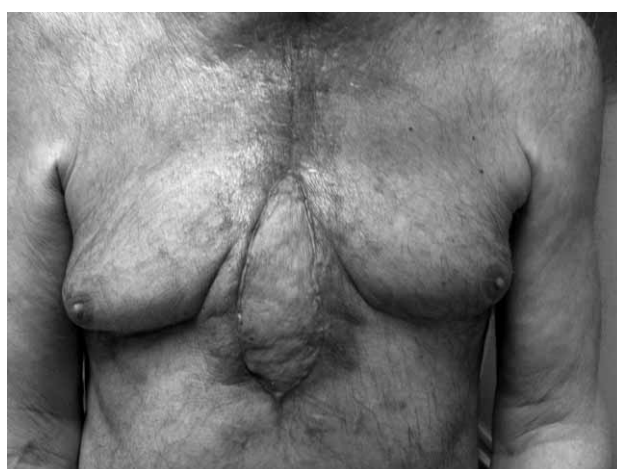

Fig. 4. Patient 1 after six month follow up.

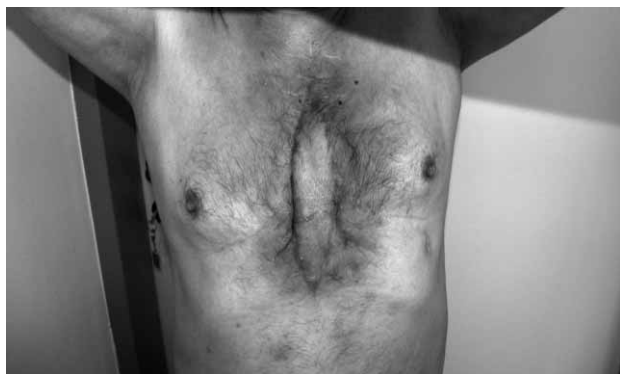

Fig. 5. Patient 2 after four month follow up.

construction was 20 days. Both patients recovered completely (Figure 4 and 5).

No donor-site complications like abdominal wall infection, ventral hernia, ileus or hemorrhage were found.

Surgical Technique

The laparoscopic part of the operation lasted 40 minutes.

Under general anesthesia, the patient is placed in the supine position and abdomen prepared with betadine and draped. A 10-mm Hasson trocar is placed through a supraumbilical incision. After artificial pneumoperitoneum is achieved, a telescopic camera is passed and 5-mm ports are placed in the right and left abdomen, lateral of the umbilicus in the middle clavicular line.

The omentum is freed from the greater curvature of the stomach by dividing the short gastric arteries and later separated from the transverse colon. The blood supply is evaluated by identifying the right and the left gastroepiploic arteries. The pedicle was based on the right gastroepiploic artery, because of its greater length. The sternal or mediastinal wound is then debrided with removal of necrotic bone, cartilage, and sternal wires. A slit in the diaphragm is made via the sternal defect be-

side the falciform ligament. Under laparoscopic visualization, the omentum is guided into the sternal cavity. The pedicle and blood supply were checked several times to prevent strangulation in the thoracic wall which could endanger the pedicle and its blood supply. The omentum is then used to obliterate the mediastinal defect and the cavity is secured in place with absorbable sutures (2–0 Vicryl). Split thickness skin graft was harvested from the upper thigh and applied on the top of the omentum.

Discussion and Conclusion

The introduction of minimally invasive surgical techniques and their widespread dissemination during the last decade have proved extremely beneficial. Laparoscopic procedures have easier and faster postoperative recovery, and less wound and pulmonary morbidity than the traditional ones. Using laparoscopy to obtain an omental flap for reconstruction of thoracic or other extra-abdominal wounds avoids the disadvantages associated with laparotomy.

Vacuum-assisted closure (VAC) is a recent technical innovation in wound care with a growing number of applications. VAC allows open drainage that continuously removes exudate with simultaneous stabilization of the chest and isolation of the wound. By maintaining a moist environment, this therapy stimulates granulation-tissue formation in combination with an increased blood flow in the adjacent tissue. VAC therapy approximates the wound edges and provides a mass filling effect with a low degree of surgical trauma, without establishing a new wound, and finally patients can be mobilized early and receive physiotherapy in order to minimize further complications. VAC therapy was induced before the reconstruction, because it provides the perfect conditions for graft take such as a suitable wound bed, firm fixation and prevention of shearing forces, adaptation to various concave or convex surfaces and reduction of infection^{8–13}.

Vacuum-assisted closure treatment combined with laparoscopic mobilization of great omentum is suitable option for treating poststernotomy mediastinitis.

REFERENCES

1. JULIAN OC, LOPEZ-BELIO M, DYE WS, *Surgery*, 42 (1957) 753.
2. BAHAIR HG, GRANT WC, LOSKEN A, *Ann Plast Surg*, 60 (2008) 169.
3. MANGRAM AJ, HORAN TC, PEARSON ML, SILVER LC, JARVIS WR, *Am J Infect Control*, 27 (1999) 97.
4. SJÖGREN J, MALMSÖ-JÖ M, GUSTAFSSON R, INGEMANSSON R, *Eur J Cardiothorac Surg*, 30 (2006) 898.
5. SALTZ R, STOWERS R, SMITH M, *Ann Surg*, 217 (1993) 542.
6. SALTZ R, *Clin Plast Surg*, 584 (1995) 45.
7. ACAR-TURK TO, SWARTZ WM, LUKETICH J, QUINLIN RF, EDINGTON H, *Ann Plast Surg*, 53 (2004) 210.
8. AVITAL S, ROSIN D, BRASESCO O, SABER AA, GUPTA A, BOYD B, ROSENTHAL RJ, *Ann Plast Surg*, 49 (2002) 308.
9. SAIKI Y, KAWAMOTO S, SAI S, TABAYASHI K, *Inter-*

10. FERON G, GARRIDO I, MARTEL P, GESSON-PAUTE A, CLASSE JM, LETOURNEUR B, QUERLEU D, *Ann Plast Surg*, 58 (2007) 150.
11. HOUNTIS P, DEDELIAS P, BOLOS K, *Cases Journal*, 2 (2009) 142.
12. MORYKWA MJ, ARGENTA LC, SHELTON-BROWN EI, MCGUIRT W, *Ann Plast Surg*, 38 (1997) 553.
13. ERSOZ G, AYTACOGU BN, SUCU N, TAMER L, BAYINDIR I, KOSE N, KAYA A, DIKMENGIN M, *BMC Infect Dis*, 6 (2006) 76.
14. HULTMANN CS, CARLSON GW, LOSKEN A, JONES G, CULBERTSON J, MACKAY G, BOSTWICK J, JURKIEWICZ MJ, *Ann Surg*, 238 (2002) 782.

Z. Veir

*Department of Plastic Surgery, University Hospital Center Zagreb, Kišpatićeva 12, 10 000 Zagreb Croatia
e-mail: veir.zoran@gmail.com*

VAKUM POTPOMOĞNUTO LIJEČENJE I LAPAROSKOPSKI MOBILIZACIJA VELIKOG OMENTUMA U LIJEČENJU TEŠKIH INFEKCIJA RANA PRSNE KOSTI: PRIKAZ DVA SLUČAJA

S A Ž E T A K

U kardijalnoj kirurgiji nakon operativnog zahvata, infekcija rane može biti fatalna. Mortalitet doseže čak do 50%. Opisali smo dva bolesnika, koji su nakon ugradnje srčane premosnice razvili tešku infekciju rane prsne kosti. Liječenje je započeto vakum pumpom, zatim je korišten laparoskopski pristup za mobilizaciju velikog omentuma te je veliki omentum pokriven s režnjem kože dijelomične debljine. Veliki omentum je izvrsno vaskularizirano tkivo, velike površine s odličnim imunološkim svojstvima. Također omentum potiče rast novih krvnih žila. Oba bolesnika u potpunosti su se oporavila. Po našem mišljenju kombinacija vakum potpomognutog liječenja te mobilizacija omentuma laparoskopskom tehnikom, predstavlja dobar način liječenja za teže infekcije prsne kosti.