

Parvovirus B 19 (PVB19) induced pure red cell aplasia (PRCA) in immunocompromised patient after liver transplantation

Mrzljak, Anna; Kardum-Skelin, Ika; Čolić Cvrlje, Vesna; Filipec Kanižaj, Tajana; Šušterčić, Dunja; Guštin, Denis; Kocman, Branislav

Source / Izvornik: *Collegium Antropologicum*, 2010, 34, 271 - 274

Journal article, Published version

Rad u časopisu, Objavljena verzija rada (izdavačev PDF)

Permanent link / Trajna poveznica: <https://urn.nsk.hr/urn:nbn:hr:105:082433>

Rights / Prava: [In copyright](#) / [Zaštićeno autorskim pravom](#).

Download date / Datum preuzimanja: **2024-07-10**



Repository / Repozitorij:

[Dr Med - University of Zagreb School of Medicine Digital Repository](#)



Parvovirus B 19 (PVB19) Induced Pure Red Cell Aplasia (PRCA) in Immunocompromised Patient after Liver Transplantation

Anna Mrzljak^{1,4}, Ika Kardum-Skelin^{1,4}, Vesna Čolić Cvrlje^{1,4}, Tajana Filipec Kanižaj^{1,4}, Dunja Šušterčić¹, Denis Guštin³ and Branislav Kocman³

¹ Department of Medicine, University Hospital »Merkur«, Zagreb, Croatia

² Department of Anesthesiology and Intensive Care, University Hospital »Merkur«, Zagreb, Croatia

³ Department of Surgery, University Hospital »Merkur«, Zagreb, Croatia

⁴ University of Zagreb, School of Medicine, Zagreb, Croatia

ABSTRACT

Presented here is a case of human parvovirus B19 (PVB19) induced pure red-cell aplasia (PRCA) in immunocompromised patient after orthotopic liver transplantation (OLT). PVB19 is a small, single-stranded DNA whose target cell is the erythroid progenitor in bone marrow. Manifestations of PVB19 infection vary with the immunologic status of the patient, ranging from asymptomatic to severe infections and PRCA. Post-transplant PRCA is induced either by immunosuppressive agents or PVB19. In the presented case, bone marrow aspiration characterized by the absence of mature erythroid precursors and detection of PVB19 DNA in blood led to treatment with high-dose intravenous human immunoglobulins (IVIG) and subsequent recovery of erythropoiesis. Due to insufficient antibody response in immunocompromised patients, suppression of the PVB19 infection is delayed and repetitive treatments may be administered in attempt of reversing PRCA.

Key words: pure red-cell aplasia (PRCA), parvovirus B19 (PVB19), liver transplantation

Introduction

Pure red-cell aplasia (PRCA) is a syndrome defined by the absence of mature erythroid precursors in a bone marrow. Etiology is heterogeneous, including congenital and acquired forms. Acquired PRCA may develop in association with autoimmune disorders, neoplastic disorders, drugs or as a consequence of chronic infection with human parvovirus B19 (PVB19)¹. The PVB19 target cell is the erythroid progenitor in bone marrow. Primary infection is asymptomatic in most of the cases, although acute infection can result in arthritis or *erythema infectiosum* (»fifth« disease) and chronic infection with PRCA in immunocompromised patients.

PVB19 induced PRCA has been rarely reported after solid organ transplantation, whereas majority of reported cases develop after kidney transplantation (KT).

Up till now there have been reported only 8 cases of PVB19 chronic infection after liver transplantation (LT) in the literature². This severe complication usually re-

sponds to high-dose intravenous human immunoglobulins (IVIG) with subsequent recovery of erythropoiesis³, but relapses are common. Reported here is a case of PVB19 induced PRCA in immunocompromised patient after LT with systematic review of the present literature.

Case Report

A 58 years old man with end-stage liver disease due to alcoholic liver cirrhosis underwent in May 2008 orthotopic liver transplantation. His postoperative period was complicated with right-sided bronchopneumonia and deterioration of renal function which led to haemofiltration. On postoperative day (POD) 12 his renal function improved and haemofiltration was ceased. His immunosuppression consisted of triple regime: mycophenolate mofetil, cyclosporine and prednisolon. Prophylaxis with valgancyclovir and trimetoprin-sulfometoxazol was initi-

ated. During first five weeks after LT a progressive drop of hemoglobin level to 62 g/L was noticed. Anti-erythrocyte antibodies tested negative. Upper GI endoscopy and colonoscopy revealed no lesions whereas urine sediment was unremarkable. Serological markers of hepatitis B, as well as cytomegalovirus (CMV) and Epstein Barr virus (EBV) DNA and HCV RNA tested negative. Bone marrow aspiration revealed normocellular smear with dense granulopoiesis demonstrating all developing stages of granulocytes, and megakaryocytes with rare giant erythroblasts indicating potential infection with *Parvoviruses*

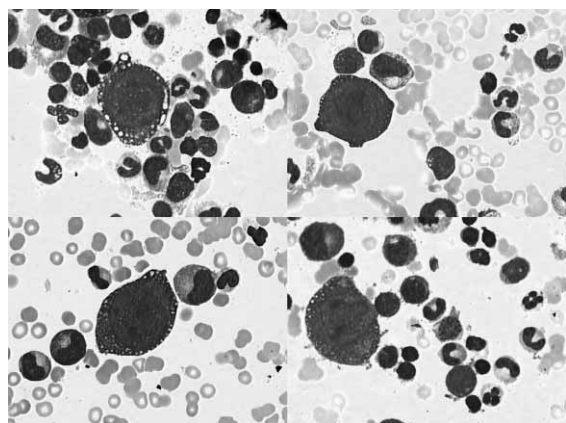


Fig. 1. May-Grünwald-Giemsa stained (1000x). Erythroid hypoplasia and the cytopathic effect of parvovirus B19 parvovirus infection of the erythroid progenitor cell. Bone marrow showing giant erythroblast.

(Figure 1).

Polymerase chain reaction (PCR) of PVB19 DNA confirmed the infection with high viral load (1.83×10^{13} copies/mL).

Initial treatment with red blood cell transfusions, followed by 10-days course of human immunoglobulins (400 mg per kilogram) was started, followed by recovery of hemoglobin level up to 115 g/L and sharp decline in viral load to 1.8×10^5 copies/mL. Due to mild acute cellular graft rejection the patient received corticosteroid pulses after which a rise in viral load up to 4.17×10^{10} copies/mL and subsequent drop in hemoglobin level were noticed. Further treatment with red blood cell transfusions and two more courses of IVIG resulted in viral load decline and recovery of hemoglobin levels. During one year follow-up period the patient maintained a low-level viremia without recurrence of PRCA (Figures 2 and 3).

Discussion

Anemia is a frequent problem after LT, with its heterogeneous etiology it can be presented as hyper-regenerative due to blood loss or haemolysis or hypo-regenerative due to myelotoxic drugs or infectious agents or combination of both types. One of hypo-regenerative anemias is a pure red cell aplasia (PRCA) characterized by the inhibition of erythropoiesis in bone marrow. It can be heredi-

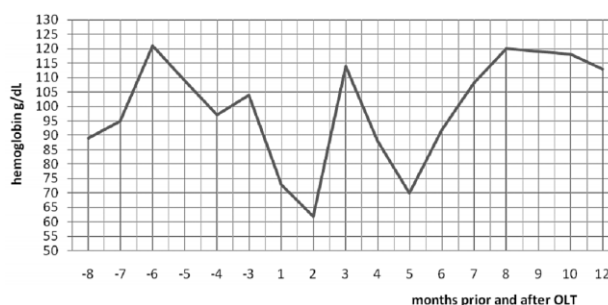

Fig. 2. Hemoglobin levels pre- and post-OLT. Therapy with red blood cell transfusions and repetitive IVIG cycles (0,4 g per kg) resulted in recovery of erythropoiesis demonstrated by monitoring hemoglobin levels during 1-year follow-up period.

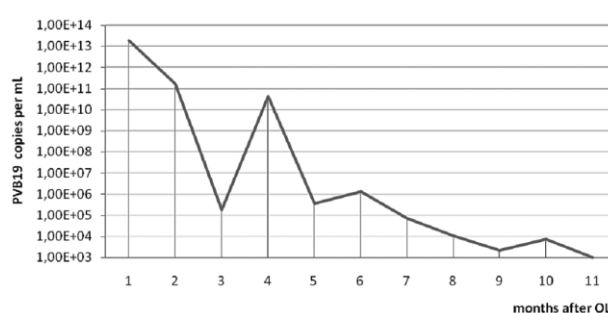


Fig. 3. Therapy response monitoring the PVB19 DNA viral load after red blood cell transfusion and IVIG during 1-year follow-up period.

tary or secondary due to multiple factors such as: drugs, toxins, infections, anti-EPO antibodies, autoimmune disorders, neoplastic disorders⁴.

PRCA after solid organ transplantation (SOT) occurs rarely and it is associated with human PVB19 or myelotoxic drugs⁵⁻⁷. Thirty drugs have been implicated as causative factors in PRCA, but most literature describes single case reports or case series. Data evaluating possible mechanisms of drug-induced PRCA are limited, with the conflicting results⁸. Immunosuppressive agents such as mycophenolate mofetil (MMF) and tacrolimus (Tac) have been implicated the most. MMF is an inhibitor of guanosine triphosphate synthesis and causes selective inhibition of B- and T-cell lymphocyte proliferation whereas tacrolimus as calcineurin inhibitor inhibits T-cell activation. MMF/Tac induced – PRCA resolves after discontinuation or dose reduction. Despite of extensive use of MMF/Tac no consistent associations between RCA and MMF/Tac have been found, indicating the complex pathogenesis which presumes qualitative alteration of the global immunosuppression status and possible broader antiproliferative effect than its proposed lymphocyte-specific effect⁹⁻¹¹. Majority of post-transplant PRCA cases develop after kidney transplantation and only few after liver transplantation. Contributing to a higher incidence of PRCA after kidney transplantation is a development of neutralizing autoantibodies against erythropoietin which is a standard treatment of anemia

in patients with end-stage kidney disease (ESKD)⁸. Erythropoietin however, is essential for terminal maturation of erythroid progenitors.

PVB19 is a small, single-stranded DNA non-enveloped virus, classified into *Parvoviridae* which was discovered in 1975^{9,10}. The virus is spread by infected droplets, blood-borne transmission and administration of blood products^{11,12}. The prevalence in the general population of IgG anti-PVB19 antibodies ranges between 50% and 70%.

Manifestations of its infection vary with the immunologic status of the host. In an immunocompetent patient after a short period of viremia, IgM and IgG antibodies are produced followed by the clearance of virus. PVB19 can cause *erythema infectiosum* («fifth» disease) in children and acute symmetric polyarthropathy in adults¹³. In contrast, immunocompromised patients are unable to produce an effective antibody response allowing maintenance of viremia and development of severe infections as well as PRCA. The presumed pathogenesis in development of PRCA is its viral tropism and direct cytotoxicity to erythroid progenitor cells leading to inhibition of erythropoiesis¹⁴.

Therapy with intravenous human immunoglobulins (IVIG) can be effective in treatment of PVB19 induced

PRCA. IVIG act as neutralizing antibodies against the virus suppressing the infection when administered in high-dose (0.4 g/kg or 1 g/kg per day)¹⁵. Such treatment however may be followed by serious side effects like fever, headache, myalgia, hypertension and acute renal failure which were not noticed in our case¹⁶.

The duration of the therapy depends on the response of the patient. Immunosuppressed patients after SOT are unable to produce an effective antibody response to the virus and therefore may require repeated courses of IVIG, delaying the recovery period. In spite of persistent low-viral load our patient did not recur with PRCA and a monitoring of viral DNA and hemoglobin level was continued during whole follow-up period.

PRCA after LT is a rare complication, mainly combined with present immunosuppression or PVB19. Although no persistent treatment strategies for PVB19 induced PRCA are present at the moment, treatment with red blood cell transfusion in combination with high doses of IVIG can be effective. Due to insufficient antibody response in immunocompromised patients, repetitive treatments may be needed in attempt of controlling the PVB19 infection and reversing PRCA.

REFERENCES

1. FISCH P, HANDGRETINGER R, SCHAEFER HE, Br J Haematol, 111 (2000) 1010. — 2. TING-BO L, DONG-LIN L, JUN Y, XUE-LI B, LIANG L, SHI-GUO X, WEI-LIN W, YAN S, MIN Z, SHU-SEN Z, World J Gastroenterol, 13 (2007) 2007. — 3. MOUTHON L, GUILLEVIN L, TELLIER Z, Autoimmun Rev, 4 (2005) 264. — 4. DJALDETTI M, BLAY A, BERGMAN M, SALMAN H, BESSLER H, Biomed Pharmacother, 57 (2003) 326. — 5. AGRAWAL A, PARROTT NR, RIAD HN, AUGUSTINE T, Transplant Proc, 36 (2004) 2689. — 6. HODO Y, TSUJI K, MIZUKOSHI E, YAMASHITA T, SAKAI A, NAKAMOTO Y, HONDA M, KANEKO S, Transpl Int, 19 (2006) 170. — 7. GREGOOR PS, WEIMAR W, Am J Transplant, 5 (2005) 195. — 8. THOMPSON DF, GALES MA, Pharmacotherapy, 16 (1996) 1002. — 9. ENGELEN W, VERPOOTEN GA, VAN DER PLANKEN M, HELBERT MF, BOSMANS JL, DE BROE ME, Clin Nephrol, 60 (2003) 119. — 10. NOSARI A, MARBELLO L, DE CARLIS LG, DE GASPERI A, MUTI G, MANCINI V, MORRA E, Int J Hematol, 79 (2004) 130. — 11. ELIMELAKH M, DAYTON V, PARK KS, GRUESSNER AC, SUTHERLAND D, HOWE RB, REDING MT, EASTLUND T, VAN BURIK JA, SINGLETON TP, GRUESSNER RW, KEY NS, Haematologica, 92 (2007) 1029. — 12. CASADEVALL N, NATAF J, VIRON B, KOLTA A, KILADJIAN JJ, MARTIN-DUPONT P, MICHAUD P, PAPO T, UGO V, TEYSSANDIER I, VARET B, MAYEUX P, N Engl J Med, 346 (2002) 469. — 13. COSSART YE, FIELD AM, CANT B, WIDDOWS D, Lancet, 1 (1975) 72. — 14. KAUFMANN B, SIMPSON AA, ROSSMANN MG, Proc Natl Acad Sci, 101 (2004) 11628. — 15. CHORBA T, COCCIA P, HOLMAN RC, TATTERSALL P, ANDERSON LJ, SUDMAN J, YOUNG NS, KURCZYNSKI E, SAARINEN UM, MOIR RJ, Infect Dis, 154 (1986) 383. — 16. AZZI A, MORFINI M, MANNUCCI PM, Transfus Med Rev, 13 (1999) 194. — 17. YOUNG NS, BROWN KE, N Engl J Med, 350 (2004) 586. — 18. HEEGAARD ED, BROWN KE, Clin Microbiol Rev, 15 (2002) 485. — 19. MOUTHON L, GUILLEVIN L, TELLIER Z, Autoimmun Rev, 4 (2005) 264. — 20. METALLIDIS S, PAPAIOANNOU M, BOKOLAS G, KOLLARAS P, GOGOU V, NIKOLAIDIS P, Clin Nephrol, 71 (2009) 196.

A. Mrzljak

Department of Medicine, University Hospital »Merkur«, Zajčeva 19, Zagreb, Croatia
e-mail: anna.mrzljak@gmail.com

IZOLIRANA APLAZIJA CRVENE KRVNE LOZE UZROKOVANA INFEKCIJOM PARVOVIRUSOM B 19 NAKON TRANSPLANTACIJE JETRE

SAŽETAK

Prikazujemo slučaj izolirane aplazije crvene krvne loze uzrokovane humanim parvovirus B19 (PVB19) kod imunokompromitiranog bolesnika nakon transplantacije jetre. PVB19 je malen, jednolančani DNA virus čije je djelovanje usmjereno na prekursorne eritoidne stanice u koštanoj srži. Manifestacije PVB19 infekcije su raznolike, te ovise o imunološkom statusu bolesnika, a prezentiraju u rasponu od asimptomatskih do teških infekcija i izolirane aplazije

crvene krve loze. Kod transplantiranih bolesnika uzrok izolirane aplazije crvene krvne loze su imunosupresivni lijekovi ili PVB19. U prikazanom slučaju temeljem citološke analize koštane srži uz karakteristični nedostatak zrelih eritoidnih prekursora te verifikacijom PVB19 DNA u krvi postavljena je dijagnoza. Bolesnik je liječen visokim dozama intravenskih ljudskih imunoglobulina što je dovelo do oporavka eritropoeze. Međutim kod transplantiranih bolesnika, radi imunosupresivne terapije postoji nedostatan imunološki odgovor stoga je supresija infekcije PVB19 odgođena što zahtjeva ustrajnost u terapiji u cilju pokušaja reverzije izolirane aplazije crvene krvne loze.