

# First documented case of BK nephropathy in kidney transplant recipient in Croatia: usage of urine cytology in evaluation process

---

**Kovačević Vojtušek, Ivana; Gracin, Sonja; Knotek, Mladen; Ljubanović, Danica; Kardum-Skelin, Ika; Sabljar Matovinović, Mirjana**

*Source / Izvornik:* **Collegium Antropologicum, 2010, 34, 255 - 259**

**Journal article, Published version**

**Rad u časopisu, Objavljena verzija rada (izdavačev PDF)**

*Permanent link / Trajna poveznica:* <https://urn.nsk.hr/urn:nbn:hr:105:326759>

*Rights / Prava:* [In copyright](#) / [Zaštićeno autorskim pravom.](#)

*Download date / Datum preuzimanja:* **2024-08-20**



*Repository / Repozitorij:*

[Dr Med - University of Zagreb School of Medicine  
Digital Repository](#)



# First Documented Case of BK Nephropathy in Kidney Transplant Recipient in Croatia: Usage of Urine Cytology in Evaluation Process

Ivana Kovačević Vojtušek<sup>1</sup>, Sonja Gracin<sup>1</sup>, Mladen Knotek<sup>1,4</sup>, Danica Ljubanović<sup>2,4</sup>, Ika Kardum-Skelin<sup>3,4</sup> and Mirjana Sabljar Matovinović<sup>1,4</sup>

<sup>1</sup> Department of Nephrology, University Hospital »Mercur«, Zagreb, Croatia

<sup>2</sup> Department of Pathology, University Hospital Dubrava, Zagreb, Croatia

<sup>3</sup> Laboratory for Cytology and Hematology, Department of Medicine, University Hospital »Mercur«, Zagreb, Croatia

<sup>4</sup> University of Zagreb, School of Medicine, Zagreb, Croatia

## ABSTRACT

*BK virus associated nephropathy (BKVAN) in transplanted kidney, although recognized as a distinct entity in the 1970-es, continues to represent a challenge in kidney transplantation, mainly because the optimal treatment approach has not been determined yet. The fact that about 10–20% of patients have simultaneously some stage of acute rejection, complicate the treatment even more. Herein we present a case of BK nephropathy in the patient, one year after combined liver and kidney transplantation, complicated by episode of acute T-cell mediated rejection. Identification of decoy cells by cytology urine exam in patient with acute kidney graft function deterioration, raised suspicion of BKVAN. Diagnosis has been made by histological examination and confirmed with immunohistochemical staining for BK virus in kidney graft biopsy. One month after he had been treated for BKVAN with intravenous immunoglobulin, leflunomide and overall immunosuppression therapy reduction, there was further deterioration of graft function due to an episode of acute T-cell mediated rejection (Banff classification IA). He received 500 mg of metilprednisolon intravenously and mycophenolate mofetil had been reintroduced, which resulted in slow partial recovery of the graft function, but never to the baseline values. For the past two years his renal graft function has been stable, maintaining lower levels of immunosuppressive therapy. According to our knowledge this is the first documented case of BK virus associated nephropathy, diagnosed and confirmed with immunohistochemical staining of tissue from kidney biopsy in Croatia.*

**Key words:** BK virus associated nephropathy, kidney and liver transplantation, graft function, acute cellular rejection

## Introduction

BK polyomavirus, first isolated in urine of patients with transplanted kidney and ureteric stenosis in 1971., has been correlated later with distinct kidney disease in transplanted kidney. In the late 1990-ties many cases of polyoma virus or BK virus associated nephropathy (PVAN or BKVAN) were reported worldwide<sup>1–6</sup>. Incidence of BKVAN in renal transplant recipients varies from 1–10%, regarding different immunosuppressive protocols<sup>7</sup>, resulted in 50% graft loss in the early series of patients<sup>3,4,6,8</sup>. Transplant kidney biopsy is the gold standard for diagnosing BKVAN<sup>9</sup>. Demonstration of polyomavirus cyopathic changes in renal tubular epithelium on light microscopy, should be confirmed by immunohistochemical staining for BK virus<sup>5,6,10</sup>. There

are 3 main histological patterns: A with cytopathic/cytolytic changes with absent or minimal inflammation, B with cytopathic/cytolytic changes with patchy or diffuse tubulointerstitial inflammation and atrophy, and C represents graft sclerosis<sup>11</sup>. Focal distribution of the disease in the kidney could result in false negative biopsy, especially in the early phase of disease. Additional problem appears in the case of simultaneous acute T-cell mediated rejection, because inflammatory infiltrates and tubulitis could be also a part of immune response to the BK virus infection<sup>12</sup>. Presence of other signs of rejection like endarteritis, positive C4d, or fibrinoid arterial necrosis could help defining between two entities.

Different screening options and early therapeutic interventions resulted lately in lower incidence of graft loss in patients with BKVAN. Screening the urine for cells with viral inclusions, so called decoy cells, is a primary screening option in many transplant centers. BKV infected decoy cells mostly originate from the epithelium of the bladder and urethers, but part of them come directly from the renal tubules and precede appearance of BKVAN for about five to six months<sup>13</sup>.

Different accuracy of that method has been observed in different transplant centers, with positive predictive value from 40 to 90%, probably due to differences in urin examination method, as well as to the extent of histologic kidney sample evaluation<sup>11,14,15</sup>. Authors from University of Maryland School of Medicine have found the highest positive predictive value of urine cytology in evaluation of 413 patients, whom they performed detailed pathologic analysis of biopsied kidney tissue with multiple immunohistochemical staining for BK in different parts of sample, which resulted in relatively high proportion of positive biopsies<sup>11</sup>.

Quantitative and qualitative determination of BK virus in blood and urine by polymerase chain reaction (PCR), became recently the screening method of choice in many transplant centers<sup>7,9</sup>. BK viruria is typically followed within weeks by the development of BK viremia and certain threshold values ( $>10^4$  viral copies/mL) have been suggested to predict BKVAN, but there are considerable overlap of these values between recipients in different stages of the disease<sup>13,16,17</sup>. It is widely accepted, that reduction of overall immunosuppression therapy should be the first intervention for patients with BKVAN<sup>7</sup>, with different approaches in certain transplant centers<sup>18–20</sup>. Several adjuvant therapeutic agents (cidofovir, leflunomide and intravenous immunoglobulins) have been used empirically as single agent, or combined to each other, always with immunosuppressive therapy reduction, and those data were mostly retrospectively analyzed<sup>21</sup>. Reduction of immunosuppressive therapy is complicated in 25% of patients with some episode of acute, mostly T-cell mediated rejection, often responsive to steroid treatment<sup>5,7,20</sup>.

## Case Report

Herein we present a case of 20 years old Caucasian, whom were simultaneously transplanted liver and kidney in June 2006. His original disease was ARPKD and idiopathic liver fibrosis. At the time of transplantation CDC cross match was positive, which we accept for patients with liver and combined liver-kidney transplantation in our centre. Induction therapy with IL-2 receptor monoclonal antibody daclizumab and steroids was used, followed by maintenance therapy with tacrolimus, mycophenolate mofetil (MMF) and steroids. Early function of both grafts were excellent. There were some transient elevation of hepatic enzymes, but without any signs of acute rejection on liver biopsy.

One year post transplant there was an acute deterioration of renal graft function, considered prerenal, following an episode of acute viral gastroenteritis, but without improvement to fluid replacement. Simultaneously urine cytology revealed decoy cells and kidney biopsy was performed. Histology showed characteristic basophilic nuclear viral inclusions in epithelial cells of renal tubules, with diffuse inflammatory infiltrates and tubulitis, but also with areas of tubular atrophy, which was consistent with florid (histology pattern B3<sup>13</sup>) BKVAN (Figure 1). Diagnosis was confirmed by immunohistochemical staining for BK virus (Figure 2). The patient has been treated with 25 grams of intravenous immunoglobulin for 4 days and mycophenolate mofetil was replaced by 100 mg leflunomide with reduction of tacrolimus dose. After short period (1.5 month) of stable renal function, kidney biopsy has been repeated for further deterioration of graft function. Histology revealed acute T-cell mediated rejection (IIA, according to Banff classification<sup>22</sup>), with negative staining for BK virus, and we treated the patient with 500 mg of metilprednisolon and mycophenolate mofetil has been reintroduced, but kept at the lower dose. These resulted in slow partial recovery of the graft function, but never to the baseline values.

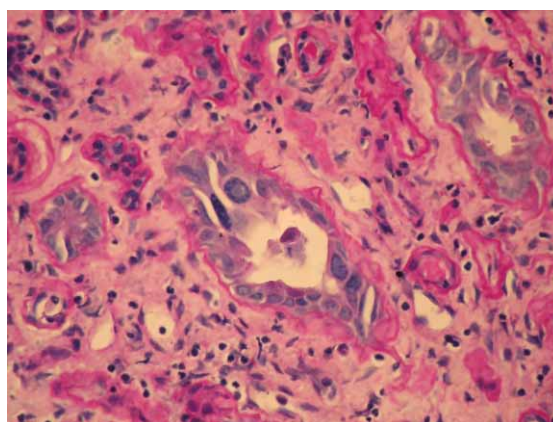


Fig. 1. BK viral inclusions in the renal tubular cells.

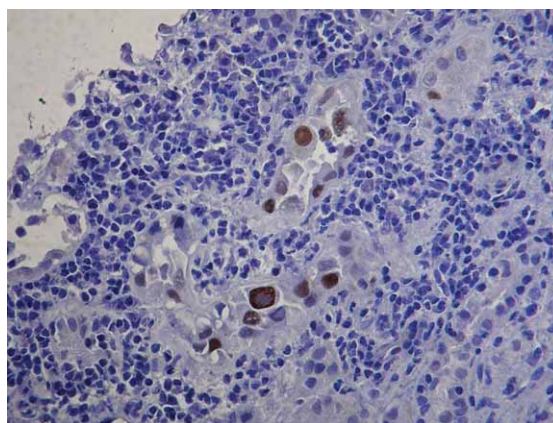


Fig. 2. Positive immunohistochemical staining for BK virus in renal tubular cells.

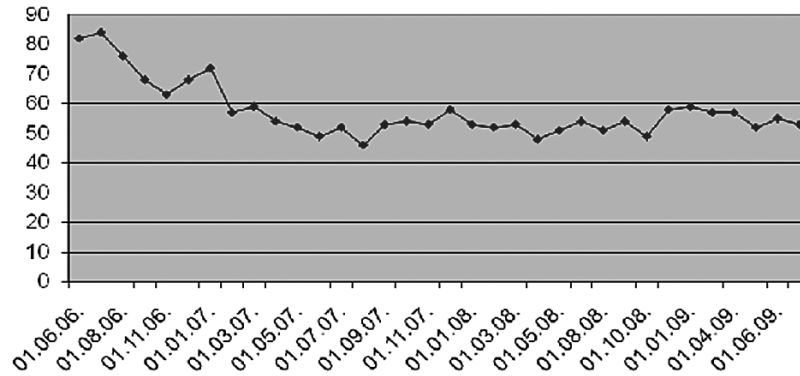


Fig. 3. Estimated glomerular filtration rate calculated by Cockcroft Gault formula in milliliters per minute.

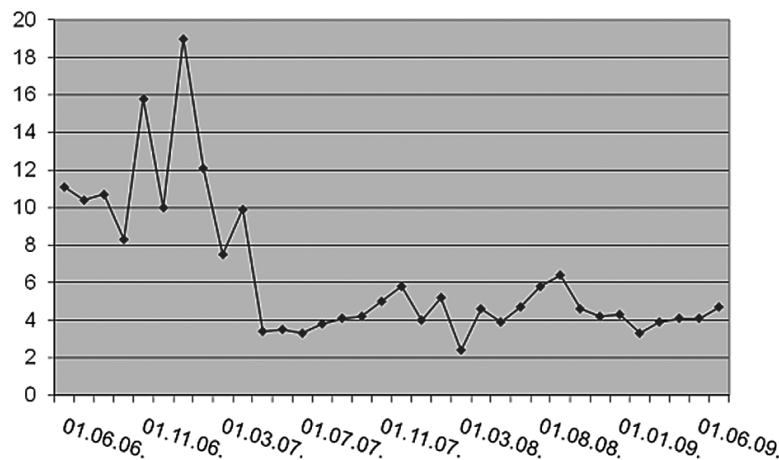


Fig. 4. Tacrolimus concentration in nanograms per milliliter in plasma.

For the past two years we have been maintaining his immunosuppressive regimen at the lower levels, succeeding to maintain his renal graft function stable (Figures 3 and 4).

## Discussion

Two different screening and intervention protocols have been proposed by two large transplant centers. One is based on urine cytology screening, with evaluation of renal biopsy when there is persistence of decoy cells in urine or viremia independently of the renal function<sup>11,18</sup>. This could potentially establish BK nephropathy in early phase of the disease, but higher rate of false negative biopsies may be encountered in that early stage, because of focal parenchymal involvement.

The other approach, proposed by Brennan and co-workers, is quantitative measurement of BK viremia, with certain cut off titer, when they reduce immunosuppression in step manure, without performing kidney biopsies. Although there is concern that this could lead to much higher percentage of acute cellular rejection, just

one patient in that group developed acute rejection episode<sup>20</sup>. There is also a concern about cost benefit for each screening procedure, especially for transplant centers with low incidence of the disease<sup>23</sup>.

In our center urine cytology screening has been introduced in 2007, as well as protocol biopsies of transplanted kidney. Total of 206 kidneys, single or combined with pancreas or liver, have been transplanted in Clinical hospital Merkur in the period from 2003 to September 2009, and 3 patients have been diagnosed with BKVAN (1.3%). Lately PCR test for BK viremia is also available. The most appropriate screening protocol is yet to be determined.

Our patient has been diagnosed in the phase of overt disease, and we treated him primarily with immunosuppression reduction and empirically with adjuvant agents, according to several studies published at that time<sup>24,25</sup>. It could be suspected that rapid discontinuation of MMF led to acute cellular rejection, because Brennan and co-workers found very low rate of acute rejection in patients treated for BKVAN with slow stepwise decrease in immunosuppression therapy, especially MMF dose<sup>18,20</sup>. Different approaches have been used regarding reduction of

maintenance immunosuppression therapy, majority starting with MMF dose reduction, or complete elimination, followed by calcineurin inhibitor dose reduction<sup>18</sup>, but recently tested association between BKN and individual immunosuppressive agents showed also significant association of BKVAN with tacrolimus and prednisone, rather than MMF, suggesting that reduction of tacrolimus dose could be the first step in reduction of maintenance immunosuppression<sup>19</sup>. Signs of endoarteritis in second biopsy and negative immunohistochemistry for BK, although it could be false negative, based our decision to treat the patient with corticosteroid bolus, and reintroduced MMF, but kept the dose of both MMF and tacrolimus at low levels. Retaining the immunosuppressive therapy at low levels for two years after that, resulted in

stable GFR for more than 2 years, which is in accordance with other studies.

## Conclusion

According to our knowledge this is the first documented case of BK virus associated nephropathy, diagnosed and confirmed with immunohistochemical staining of bioptic kidney tissue in Croatia. Prospective, multicentric studies are needed to assess different screening and treatment approaches. Early diagnosis with close monitoring of renal function seems to represent the most efficacious tool in prevention of graft loss, but longer follow-up is necessary to determine the impact of immunosuppression reduction on the long term graft outcomes.

## REFERENCES

1. PAPPO O, DEMETRIS AJ, RAIKOW RB, RANDHAWA PS, Mod Pathol, 9 (1996) 105. — 2. GARDNER SD, FIELD AM, COLEMAN DV, HULME B, Lancet, i (1971) 1253. — 3. PURIGHALLA R, SHAPIRO R, MC CAULEY J, RANDHAWA P, Am J Kidney Dis, 26 (1995) 671. — 4. BINET I, NICKELEIT V, HIRSCH HH, PRINCE O, DALQUEN P, GUDAT F, MIHATSCH MJ, THIEL G, Transplantation, 67 (1999) 918. — 5. RANDHAWA PS, DEMETRIS AJ, N Engl J Med, 342 (2000) 1361. — 6. DRACHENBERG CB, BESKOW CO, CANGRO CB, BOURQUIN PM, SIMSIR A, FINK J, WEIR MR, KLASSEN DK, BARTLETT ST, PAPADIMITRIOU JC, Hum Pathol, 30 (1999) 970. — 7. HIRSCH HH, BRENNAN DC, DRACHENBERG CB, GINEVRI F, GORDON J, LIMAYE AP, MIHATSCH MJ, NICKELEIT V, RAMOS E, RANDHAWA P, SHAPIRO R, STEIGER J, SUTHANTHIRAN, TROFE J, Transplantation, 79 (2005) 1277. — 8. RAMOS E, DRACHENBERG CB, PORTOCARRERO M, BK virus nephropathy diagnosis and treatment. Experience at the University of Maryland Renal Transplant Program. In: CECKA JM, TERASAKI PI (Eds) Clinical Transplants (UCLA Tissue Typing Laboratory, Los Angeles, 2002). — 9. BOHL DL, BRENNAN DC, Clin J Am Soc Nephrol, 2 (2007) S36. — 10. RANDHAWA P, RAMOS E, Transplantation reviews, 21 (2007) 77. — 11. DRACHENBERG RC, DRACHENBERG CB, PAPADIMITRIOU JC, RAMOS E, FINK JC, WALI R, WEIR MR, KLASSEN DK, KHALED A, CUNNINGHAM R, BARTLETT ST, Am J Transplant, 1 (2001) 373. — 12. MEEHAN SM, KADAMBI PV, MANALIGOD JR, WILLIAMS JW, JOSEPHSON A, JAVAID B, Hum Pathol, 36 (2005) 1256. — 13. DRACHENBERG CB, PAPADIMITRIOU JC, HIRSCH HH, WALI R, CROWDER C, NOGUEIRA J, CANGRO CB, MENDLEY S, MIAN A, RAMOS E, Am J Transpl, 4 (2004) 2082. — 14. NICKELEIT V, HIRSCH HH, BINET IF, GUDAT F, PRINCE O, DALQUEN P, THIEL G, MIHATSCH MJ, J Am Soc Nephrol, 10 (1999) 1080. — 15. RANDHAWA P, VATS A, SHAPIRO R, Transplantation, 79 (2005) 984. — 16. BODREAULT AA, COURTEMANCHE C, LATULIPPE E, COTE I, HOUE I, DESCHENES L, J Clin Virol, 45 (2009) 318. — 17. RANDHAWA P, HO A, SHAPIRO R, VATS A, SWALSKY P, FINKELSTEIN S, UHRMACHER J, WECK K, J Clin Microbiol, 42 (2004) 1176. — 18. WALI RK, DRACHENBERG C, HIRSCH HH, JOSHI A, MUNIVENKATAPPA R, PORTOCARRERO M, WEIR M, COOPER M, BARTLETT S, RAMOS E, Am J Transpl, 8 (2008) 283. — 19. MANITPISITKUL W, DRACHENBERG C, RAMOS E, MUNIVENKATAPPA R, PHILOSOPHE B, KLASSEN D, HARIRIAN A, Transplantation, 88 (2009) 83. — 20. BRENNAN DC, AGHA I, BOHL DL, SCHNITZLE M, HARDINGER KL, LOCKWOOD M, TORRENCE S, SCHUESSLER R, ROBY T, GAUDREAULT-KEENER M, STORCH GA, Am J Transpl, 5 (2005) 582. — 21. RAMOS E, DRACHENBERG CB, WALI R, HIRSCH HH, Transplantation, 87 (2009) 621. — 22. SOLEZ K, COLVIN RB, RACUSEN LC, HAAS M, SIS B, MENGEL M, HALLORAN PF, BALDWIN W, BANFI G, COLLINS AB, COSIO F, DAVID DSR, DRACHENBERG C, EINECKE G, FOGO AB, GIBSON IW, GLOTZ D, ISKANDAR SS, KRAUS E, LERUT E, MANNON RB, MIHATSCH M, NANKIVELL BJ, NICKELEIT V, PAPADIMITRIOU JC, RANDHAWA P, REGELE H, RENAUDIN K, ROBERTS I, SERON D, SMITH RN, VALENTE M, Am J Transpl, 8 (2008) 753. — 23. KIBERD BA, Am J Transpl, 5 (2005) 2410. — 24. SENER A, HOUSE AA, JEVIKAR AM, BOUVILLE N, MC ALISTER V, MUIRHEAD N, REHMAN F, LUKE PW, Transplantation, 81 (2006) 117. — 25. WILLIAMS WW, JAVAID B, KADAMBI PV, GILLEN D, HARLAND R, THISTLEWAITE JR, GARFINKEL M, N Engl J Med, 352 (2005) 1157.

I. Kovačević Vojtušek

Department of Nephrology, University Hospital »Merkur«, Zajčeva 19, 10000 Zagreb, Croatia  
e-mail: ikovacevicvojtušek@gmail.com

## **PRVI POTVRĐENI SLUČAJ BK VIRUSNE NEFROPATIJE U BOLESNIKA SA TRANSPLANTIRANIM BUBREGOM U HRVATSKOJ: KORIŠTENJE CITOLOŠKE ANALIZE URINA U OTKRIVANJU BOLESTI**

### **S A Ž E T A K**

BK virusna nefropatija, koja je prepoznata kao posebni entitet u transplantiranom bubregu još tijekom 1970-tih godina, i dalje predstavlja dijagnostički i terapijski izazov u transplantacijskoj medicine. Otprilike 10–20% bolesnika istovremeno razvije određeni stupanj akutnog odbacivanja grafta bubrega, što dodatno komplicira pristup liječenju. Prikazujemo slučaj nefropatije uzrokovane BK virusom u bolesnika, godinu dana nakon istovremene transplantacije bubrega i jetre, čije liječenje je dodatno komplicirala epizoda akutnog odbacivanja bubrega. Temeljem citološke analize i nalaza tzv. »decoy« stаница u urinu bolesnika sa akutnim pogoršanjem funkcije grafta bubrega, postavljena je sumnja na BK virusnu nefropatiju, a dijagnoza je postavljena temeljem patohistološke analize bioptata tkiva bubrega i specifičnog imunohistokemijskog bojenja tkiva na BK virus. Bolesnika smo liječili smanjenjem ukupne doze imunosupresivne terapije, uz adjuvantnu intravensku primjenu humanog imunoglobulina, te zamjenom mikofenolat mofetila sa leflunomidom. Mjesec dana nakon početka liječenja dolazi do daljnjeg pogoršanja bubrežne funkcije, uzrokovane patohistološki dokazanom epizodom akutnog odbacivanja posredovanog T-limfocitima. Bolesnik je liječen parenteralno Solu-medrolom, uz ponovo uvođenje mikofenolat mofetila, čime se funkcija grafta bubrega djelomično oporavlja i ostaje stabilna tijekom posljednje dvije godine, uz trajno nižu razinu ukupne imunosupresivne terapije. Temeljem našeg saznanja, radi se o prvom potvrđenom slučaju BK nefropatije u bolesnika s transplantiranim bubregom u Hrvatskoj, čija je dijagnoza postavljena temeljem specifičnog imunohistokemijskog bojenja tkiva bubrega na BK virus.