

Pallister Killian syndrome: unusual significant postnatal overgrowth in a girl with otherwise typical presentation

Huljev Frković, Sanda; Tonković Đurišević, Ivana; Lasan Trčić, Ružica; Sarnavka, Vladimir; Crkvenac Gornik, Kristina; Mužinić, Dubravka; Letica, Ljiljana; Barić, Ivo; Begović, Davor

Source / Izvornik: *Collegium Antropologicum*, 2010, 34, 247 - 250

Journal article, Published version

Rad u časopisu, Objavljena verzija rada (izdavačev PDF)

Permanent link / Trajna poveznica: <https://um.nsk.hr/um:nbn:hr:105:393467>

Rights / Prava: [In copyright](#) / [Zaštićeno autorskim pravom](#).

Download date / Datum preuzimanja: **2024-09-28**



Repository / Repozitorij:

[Dr Med - University of Zagreb School of Medicine Digital Repository](#)



Pallister Killian Syndrome: Unusual Significant Postnatal Overgrowth in a Girl with otherwise Typical Presentation

Sanda Huljev Frković¹, Ivana Tonković Đurišević¹, Ružica Lasan Trčić¹, Vladimir Sarnavka¹, Kristina Crkvenac Gornik¹, Dubravka Mužinić^{1,2}, Ljiljana Letica¹, Ivo Barić^{1,2} and Davor Begović^{1,2}

¹ Division of Genetics and Metabolism, Department of Pediatrics, University Hospital Centre Zagreb, Zagreb, Croatia

² University of Zagreb, School of Medicine, Zagreb, Croatia

ABSTRACT

Pallister Killian syndrome (PKS) is a rare genetic disorder caused by tetrasomy of the short arm of chromosome 12, revealed usually in mosaic distribution of an extra i(12)(p10) chromosome in fibroblasts. The syndrome presents with a recognizable pattern of findings including pigmentary skin changes, coarse face, high forehead, sparse anterior scalp hair, hypertelorism, seizures and progressive psychomotor developmental delay. It was first described independently by Pallister in 1977 and by Killian and Teschler-Nikola in 1981^{1,2}. We report a case of 21 month old girl with PKS and significant overgrowth. Cytogenetic analysis was performed using the GTG banding technique. The karyotype of cultured lymphocytes was normal. The karyotype from skin fibroblasts was established as mosaic tetrasomy of 12p 47,XX,+i(12)(p10)/46,XX. The origin of the extra marker chromosome was determined by fluorescence in situ hybridization with chromosome 12 specific DNA probes confirming that supernumerary marker is chromosome i(12p) in 68% of cells. Despite the excessive postnatal growth we found low serum growth hormone levels and reduced response to pharmacological stimulation test. This is also the first report of a postnatal patient in our country.

Key words: *Pallister-Killian syndrome, isochromosome 12p, fibroblasts, overgrowth*

Introduction

Pallister-Killian syndrome is a dysmorphic condition involving most organ systems, but also characterized by a tissue-limited mosaicism; most fibroblasts have 47 chromosomes with an extra small metacentric chromosome, whereas the karyotype of lymphocytes is normal. The extra metacentric chromosome is an isochromosome for part of the short arm of chromosome 12: i(12)(p10). The syndrome was first described independently by Pallister in 1977 and by Killian and Teschler-Nikola in 1981^{1,2}. It presents with a recognizable pattern of findings including pigmentary skin changes, mental retardation, congenital hypotonia, seizures and facial anomalies, such as hypertelorism, coarse face, broad high forehead, sparse eyebrows and eyelashes, abnormal ears, macrostomia, short nose with anteverted nostrils, broad nasal bridge, sparse anterior scalp hair, short neck. Hearing deficit, congenital heart defects, accessory nipples, distal digital hypoplasia, diaphragmatic hernia, anal and genito – urinary abnormalities are also present. Growth pattern in

these children is characterized by normal to increased birth length with postnatal deceleration of length, normal to increased birth weight with postnatal obesity, and normal to increased head circumference at birth, with postnatal deceleration of its growth³⁻⁵. Some newborns were reported as unusually large. The cause for macrosomia is unknown. Syndrome has very low recurrence risk, all described cases were sporadic.

We report a case of 21 month old girl with PKS and significant postnatal overgrowth. The karyotype from skin fibroblasts was established as mosaic tetrasomy of 12p 47,XX,+i(12)(p10)/46,XX. The origin of the extra marker chromosome was confirmed by fluorescence *in situ* hybridization, consistent with Pallister-Killian syndrome. Despite of excessive postnatal growth we found low serum GH levels and reduced response to pharmacological stimulation test. This is also the first report of postnatal patient in our country.

Clinical Report

The patient was born at term following normal pregnancy, by spontaneous vaginal delivery. The 40-year-old father and 34-year-old mother are healthy and unrelated. Birth weight was 3150 g (25 to 50th centile), length was 49 cm (25 to 50th centile) and head circumference 37 cm (75–90th centile). Apgars were 7 and 8. The child was hypotonic with facial dysmorphism and relative macrocrania. She had one episode of seizures in the second day of life treated with phenobarbital, metabolic disturbances such as hypoglycemia, hypocalcemia and hypomagnesemia were excluded. Peripheral blood chromosome analysis performed in the first month of life in another hospital showed normal karyotype. DNA analysis for muscular dystrophy was negative.

During the first months of life mother noticed several areas of skin hypopigmentation. Due to delayed motor milestones, physical therapy was started without significant progress. After several acute middle ear infections and suspected hearing loss, otorhinolaryngological evaluation was performed and sensory hearing loss was confirmed. Despite normal calorie intake child showed excessive postnatal growth (increased weight, length and head circumference).

At the age of 21 months the patient was referred to our Department for genetic reevaluation. At this time she was overweight with 18.5 kg (+4.3 SD), with length 93 cm (+2.89 SD), head circumference 53 cm (+4.5 SD), BMI 21.5 kg/m². She had marked muscular hypotonia and severely delayed psychomotor development (constant position on back, severely reduced spontaneous movements, did not follow objects in front of her, did not sit by herself). Her face was coarse, with high forehead, frontal bossing, hypertelorism, broad nasal bridge and anteverted nostrils. Bilateral frontotemporal alopecia and sparse eyebrows were also noticed. She had hypopigmented skin areas on forehead, in lumbal region and on back side of thighs.

Because of overgrowth we evaluated growth hormone (GH) levels with L dopa stimulation test and found low serum GH levels and reduced response to pharmacological stimulation test. Insulin-like growth factor (IGF-1) and insulin-like growth factor binding protein 3 (IGF BP3), insulin and glucose levels were normal.

Brain MRI, similar to previous reports⁶, showed prominent atrophy of supratentorial parenchyma with frontal and temporal predominance, dilatation of subarachnoidal spaces, periventricular leucomalacia with volume reduction of white mater and atrophy of corpus callosum. Glandula pinealis was enlarged 10 mm in diameter, inhomogenic, without signs of compression.

Visual evoked potentials showed impaired retinocortical conduction. Heart ultrasound showed tricuspidal valve insufficiency. Abdominal ultrasound was normal.

Cytogenetic Studies

Methods

The chromosome analyses were performed on metaphases derived from peripheral blood and skin fibroblasts. Skin biopsy was taken from pigmented and hypopigmented areas of her leg and set up in culture flasks for long – term culture cytogenetic analysis. The fibroblasts were fed in culture media following which the cells divided and grew as a single layer attached to the culture flask surface producing cell colonies. Cultures were harvested when colonies were sufficient, 9–15 days after seeding. The cells were removed from original culture flasks following mitotic arrest with colchicine and treatment with trypsin. When most of the cells were floating freely, culture medium was added. The cells were then centrifuged and media and mitotic inhibitor removed and replaced with a hypotonic KCl solution. This caused the cells to swell so that the chromosomes would spread when added to a slide. After the cells have been allowed to rest in hypotonic solution the fixative (3:1 methanol to glacial acetic acid) was added, which ensured the removal of cytoplasm and cell debris. The fixed cell suspension was then dropped onto microscope slides. After aging the slides were ready for banding and analysis. Routine chromosome analysis refers to analysis of metaphase chromosomes which have been banded using trypsin followed by Giemsa. G-banded chromosome studies were performed from peripheral blood lymphocytes and skin fibroblast cultures of the patient following standard protocols⁷. Fluorescence *in situ* hybridization (FISH) techniques were employed to identify the chromosomal origin of the marker chromosomes. FISH study on metaphases and interphases of peripheral blood lymphocytes and cultured fibroblasts was performed according to standard procedure. Centromere, whole paint probe 12 and locus specific 12p13 probe were used (Q-biogene)⁸. Karyotypes were described in accordance with the International System for Human Cytogenetic Nomenclature (ISCN) 2005⁹.

Results

Chromosome analysis of patient's peripheral blood lymphocytes showed no evidence of chromosomally abnormal cells and revealed a normal karyotype. It was confirmed by fluorescence *in situ* hybridization using a 12 centromeric probe.

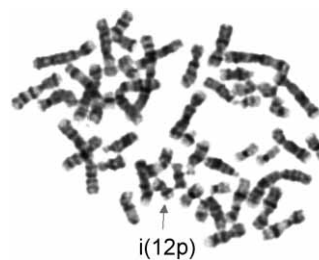


Fig. 1. GTG-banded metaphase in cultured fibroblasts with isochromosome 12p 47,XX,+i(12)(p10).

The marker chromosome was found in cultured fibroblasts from pigmented and hypopigmented skin biopsy. Standard G-banding techniques revealed a mosaic karyotype 47,XX,+i(12)(p10)/46,XX (Figure 1). Tetrasomy for the short arm of chromosome 12 was documented in 19/30 of the cells from pigmented skin. In hypopigmented skin proportion was 22/35 of tetrasomy 12p (Figure 2). The chromosomal nature of marker chromosomes was investigated by fluorescent *in situ* hybridization with biotinylated or digoxigenin labelled probes: the chromosome 12 centromere probe, 12 whole-painting probe (Figure 3) and locus specific 12p13 (TEL)/21q22 (AML1) probe (Figure 4). It was confirmed that the supernumerary marker was isochromosome 12p in 68% of cells. A whole chromosome 12 painting probe stained the marker chromosome completely. Our approach, using locus specific 12p13 probe showed four fluorescence-positive spots and has high specificity and sensitivity for the diagnosis of the real distribution of the isochromosome 12p in various tissues.

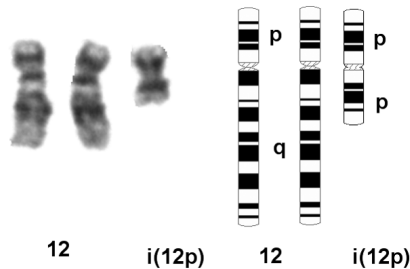


Fig. 2. Partial karyogram of isochromosome 12p with idiograms.

Discussion

The Pallister Killian syndrome (PKS) is characterized by tissue-limited mosaicism for tetrasomy 12p. All reported cases of syndrome have occurred sporadically.

The incidence of metaphases containing i(12p) has been reported to be 0% to 2% in lymphocytes, 50% to 100% in skin fibroblasts, and 100% in amniocytes^{10–12}. In some studies, the fibroblasts cultured from areas of altered pigmentation are said to yield a higher incidence of i(12p) metaphases¹³. In our case the presence of a supernumerary metacentric chromosome i(12p) was confined to skin fibroblasts while the karyotype of cultured lymphocytes was normal. Karyotyping of fibroblasts showed the presence of an isochromosome 12p in around 65% of the metaphases. In our study there was no difference of marker chromosome frequency between pigmented and hypopigmented areas of the skin.

A wide phenotypic variability has been reported ranging from perinatal death due to multiple congenital anomalies to the classical phenotype including facial dysmorphism and severe mental retardation^{3,14}. A correlation between the percentage of 12p tetrasomic cells in skin fibroblasts and the phenotypic severity is not striking^{4,15}. Our patient presented with most of the classical features

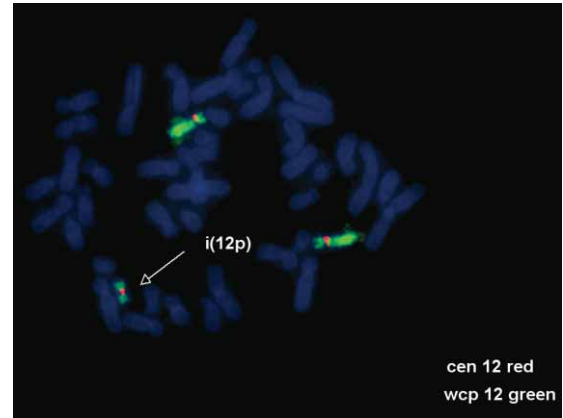


Fig. 3. Fluorescence *in situ* hybridization with chromosome 12 centromere (red) and WCP12 (green) showed chromosome 12 and isochromosome 12p.

of the syndrome: severe mental retardation, hypotonia, coarse facial appearance, broad forehead, bilateral fronto-temporal alopecia, hypertelorism, skin pigmentary changes and hearing loss^{10,15,16}.

Although prenatal and perinatal macrosomia were previously observed, growth parameters of PKS patients in further life are usually normal or a growth retardation is observed. An interesting and unusual finding in our patient is excessive postnatal growth with low growth hormone levels and reduced response to L dopa stimulation test. Possible explanation for overgrowth, similar to other described unusual findings in other reported cases, may be in the time of mosaic formation as well as somatic selection of different intensity in different tissues at different times¹⁷. On the other hand, influence of genes whose locus was assigned to 12p on overgrowth is not clarified yet.

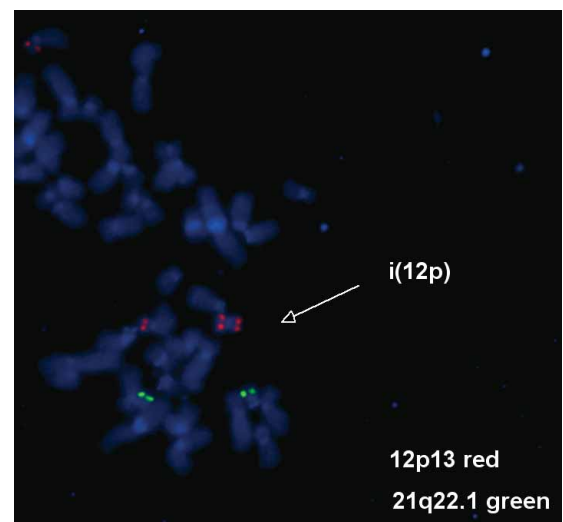


Fig. 4. Fluorescence *in situ* hybridization with locus specific probe 12p13 showed four red fluorescence-positive spots (21q22, green control signals).

Conclusions

Although tetrasomy 12p is the most frequent autosomal tetrasomy in humans, it is usually not detected during routine cytogenetic analysis of peripheral blood lymphocytes due to tissue-specific mosaicism, so many cases have likely been diagnosed as unknown congenital multiple anomaly syndrome. Clinical recognition is crucial

for the decision to perform appropriate cytogenetic investigations from different tissues. In genetic counseling is important to emphasize the low recurrence risk.

To our knowledge, previous reported patients showed normal growth parameters or growth retardation later in life. We describe a case of excessive postnatal overgrowth as a possible new feature of the syndrome.

REFERENCES

1. PALLISTER PD, MEISNER LF, ELEJALDE BR, FRANCKE U, HERRMANN J, SPRANGER J, TIDDY W, INHORN SL, OPITZ JM, Birth Defects Orig Artic Ser, 13 (1977) 103. — 2. KILLIAN W, TESCHLER-NICOLA M, Synd Ident, 7 (1981) 6. — 3. REYNOLDS JF, DANIEL A, KELLY TE, GOLLIN SM, STEPHAN MJ, CAREY J, ADKINS WN, WEBB MJ, CHAR F, JIMENEZ JF, OPITZ JM, Am J Med Genet, 27 (1987) 257. — 4. SCHINZEL A, J Med Genet, 28 (1991) 122. — 5. MATHIEU M, PIUSSAN CH, THEPOT F, GOUGET A, LACOMBE D, PEDESPAN JM, SERVILLE F, FONTAN D, RUFFIE M, NIVELON-CHEVALLIER A, AMBLARD F, CHAUVEAU, MOIROT H, CHABROLLE JP, CROQUETTE MF, TEYSSIER M, PLAUCHU H, PELLISSIER MC, GILGENKRANTZ S, TURC-CAREL C, TURLEAU C, PRIEUR M, LE MERRER M, GONZALES M, JOYE N, TAILLEMITE JL, BOUILLIE J, ESCHARD C, MOTTE J, JOURNAL H, Ann Genet, 40 (1997) 45. — 6. SAITO Y, MASUKO K, KANEKO K, CHIKUMARU Y, SAITO K, IWAMOTO H, MATSUI A, AIDA N, KUROSAWA K, KUROKI Y, KIMURA S, Brain Dev-Jpn, 28 (2006) 34. — 7. SEABRIGHT M, Lancet, 30 (1971) 971. — 8. SPELEMAN F, LEROY JG, VAN ROY N, DE PAEPE A, SUJJKERBUIJK R, BRUNNER H, LOOLJENGA L, VERSCHRAEGEN-SPAE MR, ORYE E, Am J

Med Genet, 41 (1991) 381. — 9. SHAFFER LG, TOMMERUP N (Eds), ISCN (2005): An international system for human cytogenetic nomenclature. (S. Karger, Basel, 2005). — 10. WARD BE, HAYDEN MW, ROBINSON A, Am J Med Genet, 31 (1988) 835. — 11. VERMEESCH J.R., MELOTTE C, SALDEN I, RIEGEL M, TRIFNOV V, POLITYKO A, RUMYANTSEVA N, NAUMCHIK I, STARKE H, MATTHIJS G, SCHINZEL A, FRYNS J, LIEHR T, Eur J Med Genet, 48 (2005) 319. — 12. LOS FJ, VAN OPSTAL DV, SCHOL MP, GAILLARD JLJ, BRANDENBURG H, VAN DEN OUWELAND AMW, VELD PAI, Prenat Diagn, 15 (1995) 1155. — 13. HARROD MJE, HOWARD – PEEBLES PN, FRIEDMAN JM, Proc Greenwood Genet Center, 6 (1987) 107. — 14. GENEVIEVE D, CORMIER-DAIRE V, SANLAVILLE D, FAIVRE L, GOSSET P, ALLART L, PICQ M, MUNNICH A, ROMANA S, DE BLOIS MC, VEKEMANS M, Am J Med Genet, 116 (2003) 90. — 15. BIELANSKA MM, KHALIFA MM, DUNCAN AMV, Am J Med Genet, 65 (1996) 104. — 16. BAGLAJ M, KING J, CARACHI R, J Pediatr Surg, 43 (2008) 1218. — 17. NARAHARA K, YOSHIIHARU W, KIKKAWA K, HIRAMOTO K, NAMBA H, MARAKAMI M, KASAI R, KIMOTO H, Jpn J Hum Genet, 33 (1988) 339.

S. Huljev Frković

Division of Genetics and Metabolism, Department of Pediatrics, University Hospital Centre Zagreb, Kišpatićeva 12, 10 000 Zagreb, Croatia
e-mail: sanda.huljev@zg.t-com.hr

PALLISTER KILLIANOV SINDROM: NEOBIČAN POSTNATALNI PREKOMJERNI RAST U DJEVOJČICE S INAČE TIPIČNOM KLINIČKOM PREZENTACIJOM

SAŽETAK

Pallister Killian sindrom (PKS) je rijedak genetski poremećaj uzrokovan tetrasomijom kratkog kraka kromosoma 12, koji se obično otkriva u mozaičkoj raspodjeli prekobrojnog i(12)(p10) kromosoma u fibroblastima. Sindrom se prezentira prepoznatljivim fenotipskim karakteristikama kao što su pigmentirane kožne promjene, grube crte lica, visoko čelo, rijetka kosa prednjeg dijela vlasišta, hipertelorizam, konvulzije, te progresivno psihomotorno zaostajanje. Prvi put je opisan neovisno od strane Pallistera 1977. godine, te Killiana i Teschler-Nikole 1981. godine^{1,2}. Prikazujemo slučaj dvadesetjednog mjesecne djevojčice sa PKS-om i značajnim prekomjernim rastom. Citogenetska analiza je učinjena korištenjem tehnike GTG pruganja. Kariotip kultiviranih limfocita je bio uredan. U kariotipu kožnih fibroblasta je nađena je mozaična tetrasomija 12p: 47,XX,+i(12)(p10)/46,XX. Porijeklo prekobrojnog marker kromosoma utvrđeno je fluorescentnom in situ hibridizacijom sa kromosom 12 specifičnim DNA probama. Prekobrojni marker kromosom i(12p) nađen je u 68% stanica. Uprkos ubrzanom postnatalnom rastu, utvrdili smo niske serumske razine hormona rasta uz izostanak očekivanog odgovora tijekom farmakološkog testa stimulacije. Ovo je također prikaz prvog rođenog bolesnika u našoj zemlji.