

Homocystinuria, a possible solution of the Akhenaten's mystery

Čavka, Mislav; Kelava, Tomislav; Čavka, Vlatka; Bušić, Željko; Olujić, Boris; Brkljačić, Boris

Source / Izvornik: **Collegium Antropologicum, 2010, 34, 255 - 258**

Journal article, Published version

Rad u časopisu, Objavljena verzija rada (izdavačev PDF)

Permanent link / Trajna poveznica: <https://um.nsk.hr/um:nbn:hr:105:114830>

Rights / Prava: [In copyright](#) / [Zaštićeno autorskim pravom.](#)

Download date / Datum preuzimanja: **2024-05-11**



Repository / Repozitorij:

[Dr Med - University of Zagreb School of Medicine
Digital Repository](#)



Homocystinuria, a Possible Solution of the Akhenaten's Mystery

Mislav Čavka¹, Tomislav Kelava^{2,3}, Vlatka Čavka⁴, Željko Bušić^{5,6}, Boris Olujić⁷ and Boris Brkljačić¹

¹ Department of Diagnostic and Interventional Radiology, University Hospital Dubrava, Zagreb, Croatia

² Department of Physiology, Faculty of Medicine, University of Mostar, Mostar, Bosnia and Herzegovina

³ Department of Physiology, School of Medicine, University of Zagreb, Zagreb, Croatia

⁴ Department of Dermatology and Venereology, University Hospital »Sestre milosrdnice«, Zagreb, Croatia

⁵ Department of Surgery, University Hospital Dubrava, Zagreb, Croatia

⁶ Department of Surgery, Faculty of Medicine, University of Mostar, Mostar, Bosnia and Herzegovina

⁷ Department of History, Faculty of Philosophy, University of Zagreb, Zagreb, Croatia

ABSTRACT

Pharaoh Amenophis IV (Amenhotep IV), also known as Akhenaten, is the most mysterious person in Egyptian history and he still remains the object of academic argues. This revolutionary king introduced a new concept in Egyptian religion and arts. It is still unexplained if images of him and his family were just an artistic outbreak from old Egyptian canon or an excellent paleopathological study. Several pathologic conditions were proposed to explain his appearance but neither is completely acceptable. We propose a different disease that he could have suffered of: homocystinuria – lack of cystathionine-synthase. Our conclusion is that in comparison with up to date most convincing theory, that he was suffering of Marfan syndrome, our theory equally well explains his physical appearance but is better in explaining affecting and unaffected of his relatives. This is the only theory about Akhenaten's disease that could be checked in the near future.

Key words: Egypt, history of medicine, Akhenaten, ancient history, pharaoh, homocystinuria

Introduction

Amenhotep IV (Amenophis IV in Greek) was a hereditary pharaoh of the Eighteenth dynasty, the most glorious Egyptian dynasty. The dynasty rose to power after chasing foreign sovereigns from Egypt around 1550 B.C. (1552 B.C. conventional chronology) (1550 B.C. low chronology). They are considered as the founders of the New Kingdom¹. The most famous representatives of the XVIII dynasty are: Queen Hatshepsut, the builder of magnificent temple in the Valley of queens and organizer of the well known expedition in the land called Punt; Tutmosis III, the pharaoh with the largest Egyptian territorial expansion and Tutankhamon, a young pharaoh who became world known after the discovery of his unrobed tomb. Amenhotep IV (Amenophis IV in Greek) became the king in 1364 B.C. (conventional chronology) or 1352 (low chronology) B.C.¹. and changed his name in Akh-

-en-Iten (the one who serves Aten) or simplified – Akhenaten². He was the son of Amenophis III and his wife Tiye. With his great royal wife Nefertiti he had six daughters. He was, most probably, the father of Tutankhamon with his other wife Kiya. Although several other theories about Tutankhamon descendant exist it is generally accepted that he was not son of Akhenaten and Nefertiti. Akhenaten conducted a religious reformation; he replaced the state god Amon, originally Theban god, with the god Aten, represented as sun disk. With this act he generated the conflict with mighty Theban priests, but he did not replace polytheism with monotheism what has been often thought in the last two centuries². In the 4th year of reign, he has founded the new capital – Akhetaten (horizon of Aten) in the middle of the country 320 km away from the Thebes, as he has wanted to em-

phasize even more radical changes in the society¹. Ancient city is situated near today's city of Tell el Amarna, after which the whole era is called the Amarna period. With Akhenaten's death, the Aten cult he had founded fell out of favor. His son Tutankhaten (the live image of Aten) changed his name to Tutankhamon (the live image of Amon)² in second year of his reign (1332 B.C.) and abandoned the city of Akhetaten, which eventually fell into ruin. Successive kings, starting with generals Ai and Horemheb and continuing with the XIX dynasty of Ramessids, was trying to erase every sign of Amarna period. Most probably they burned the Akhenaten's mummy, as this act in ancient Egypt meant a second and permanent death². This made things very difficult for today's historians as very little evidence is preserved. Except religious reformation the Amarna period was also characterized by the outbreak from archaic Egyptian canon, and artists started to represent pharaoh in the grotesque way (with a sagging stomach, thick thighs, larger breasts, and long, thin face). In those images his family is represented very similar (Figure 1); but other details, like animals or wheat are highly realistic. The famous relief from the Metropolitan Museum of Art in New York, where he was pictured while sacrificing a duck is typical example of his grotesque figure and realistic animal (Figure 2). It is still unexplained if this was just a form of artistic way of creating distance from traditional Egyptian art or this was his real appearance. Assuming that the latter is the truth several illnesses were proposed in attempt to explain his physical appearance, but none of those proposals is completely suitable and the exact illness remains an object of argues among the paleopathologists.

The Hypothesis

Our hypothesis is that Akhenaten was suffering of homocystinuria. In next section we will first make a critical review of up-to-date theories and then we will explain advantages and disadvantages of our theory.



Fig. 1. Akhenaten with his wife and daughters (Wikipedia commons).

Discussion

Akhenaten is often shown with elongated head, face and whole body; he has ptosis, undeveloped thorax with gynecomastia, lower abdomen prominent and relaxed, limbs and fingers elongated and large hips and legs. His wife Nefertiti and their six daughters are presented similarly, but his parents (Amenophis III and Tiye) and his son with other wife, Tutankhamon, were never pictured in this way. To recapitulate; if we suppose that images are realistic, which is a starting ground for all theories about Akhenaten's disease, the conclusion is that Akhenaten, Nefertiti and their six daughters were affected and Akhenaten's parents and Tutankhamon were unaffected. Several theories tried to explain his unorthodox appearance. Burrige offered the most convincing diagnosis. She claims that Akhenaten was suffering of Marfan syndrome³. This theory is good to explain his physical appearance and relatively short life, since Marfan syndrome is presented with triad; skeletal changes, aortal aneurysm and lens dislocation. Patients are tall and skinny, their fingers are elongated, thorax has deformities and sternum is prominent. Extremities are elongated and a highly arched palate confirms the diagnosis. Dilatation of aorta is threatening in disrupting and it can easily dissect. Ocular lens is dislocated upward. Patients die most often because of aortal damages⁴. Average life expectancy is between 30 and 40 years⁵. The main problem of this theory is that Marfan syndrome is inherited autosomal dominant and Akhenaten's parents were unaffected. An explanation could be that sporadic mutation happened, which happens in about one quarter patients with Marfan syndrome⁶. Further, since he and Nefertiti were affected the probability that one of their daughters would be ill is 75% and probability that all six daughters would be ill is $0.75^6=17\%$. Although this combination seems unlikely, it is certainly not impossible, just to mention a probability that all six children would be female was even smaller ($0.5^6=1.5\%$), but they were. However, as we will show later, if we suppose that he had homocystinuria instead of Marfan syndrome, far less circumstances should be matched. Interestingly, there is already one historical person to whom Marfan syndrome was misdiagnosed posthumously; Abraham Lincoln. In 1962 it was proposed by Gordon that Abraham Lincoln, because of his physical appearance was suffering of Marfan syndrome⁷. Later this diagnosis was shown to be unlikely



Fig. 2. Akhenaten is sacrificing a duck (Wikipedia commons).

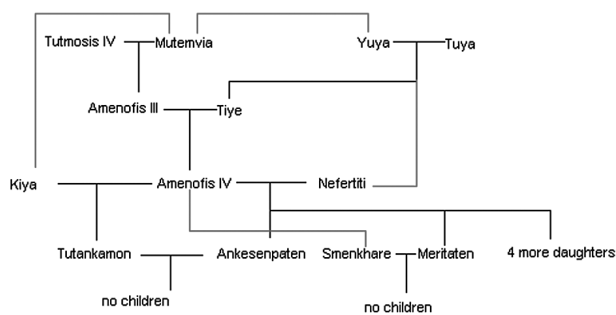


Fig. 3. Akhenaten's genealogy – red lines represent possible relationship.

and recently more possible explanation was offered; multiple endocrine neoplasia, type 2B (MEN2b), but it is still not confirmed by DNA analysis⁸. Other theories about Akhenaten's disease are less convincing. For example Elliot Smith proposed Froelich's syndrome, this is unlikely because this syndrome causes infertility⁹, so it was speculated further that the real father of Akhenaten's children was Amenophis III. If diagnosis is Klinefelter syndrome, as suggested by Paulshock the same problem with infertility arise¹⁰. Ghalioungui proposed portal hypertension with heart failure and ascites secondary to schistosomiasis and sequentially developed gynecomastia and relaxed abdomen¹¹. Myotonic dystrophy; a suggestion of Cattaino and Vicario is like Marfan syndrome autosomal dominant¹². Velikovskiy even speculated incest of Akhenaten and his mother Tiye, proposed that he had elephantiasis and since Oedipus is Greek for »swollen feet« he concluded that Akhenaten was historical figure behind Oedipus myth and moved setting from Greek to Egyptian Thebes¹³. To recapitulate the most acceptable diagnosis that can be found in literature seems to be Marfan syndrome. We now propose a new diagnosis for his condition – homocystinuria.

Homocystinuria

Classic homocystinuria is an inborn error of metabolism with autosomal recessive inheritance, characterised by the inability to convert methionine to cysteine due to a deficiency of cystathionine synthase¹⁴. Accumulation of homocysteine in tissues, blood, and urine is the consequence. Four major organ systems may be involved: the eye, the skeleton, the vascular system, and the central nervous system. Complications of the disease develop progressively if therapeutic measures have not been started at an early age¹⁵. We shall try to evaluate if Akhenaten's eyes, skeleton, vascular system and CNS were affected. Abott et al. have evaluated 63 patients and the overall rate of clinically significant psychiatric disorders was 51%, predominated by four diagnostic categories: episodic depression (10%), chronic disorders of behaviour (17%), chronic obsessive-compulsive disorder (5%), and personality disorders (19%)¹⁶. Sudden disappearing from the sources, in the 12th year of the reign, of queen Kiya¹⁷

and in the 17th year of the reign, of queen Nefertiti² and unexplained abandoning of Asian provinces¹⁸ could be explained by these psychiatric episodes. Unusual myopia (high, very high, abnormal progressive, or at young age) can be caused by subluxation of the ocular lenses¹⁹. Maybe the fascination with the sun could be explained by the ocular problems, as probably he could have seen more during the daylight. The most characteristic skeletal changes in homocystinuria are the skeletal disproportion (pubis-heel length greater than crown-pubis length), the abnormal vertebrae, sternal deformities, genu valgum and large metaphyses and epiphyses²⁰. Affected people look like Marfan syndrome's patients, and always have elongated extremities with arachnodactily. Joints tend to be tight⁴. As we have already mentioned above, his appearance was very similar. Elevated blood levels of homocysteine represent an independent risk factor for premature arterial vascular disease and thrombosis²¹. There is a 30% chance of a vascular event before the age of 20, which increases up to 50% by the age of 30¹⁵. The expected mortality in untreated patients at age 20 is 35%¹⁵. Akhenaten mounted to the throne around the age of 16 and died in his 17th regnal year⁹ at the age of 33 therefore thromboembolism could have easily been the death cause. Homocystinuria is superior to any other theory in explaining Akhenaten's family tree. Because it is autosomal recessive it explains easily why Akhenaten's parents were healthy. There are evidences that Akhenaten's parents Amenophis III and Tiye were related and that Tiye and Nefertiti were also related⁹ (Figure 3) and it is generally known that recessive inherited diseases appear more often in incest relationships. If we assume that Nefertiti was also suffering of homocystinuria (because of her appearance and possible relationship with Akhenaten this assumption is reasonable) that means that all their daughters were bound to be ill. It also explains well why Tutankhamon, his son with other wife Kiya was unaffected; he could inherit one gene for homocystinuria from his father and one healthy gene from his mother. It seems that homocystinuria can explain both his physical appearance and his family tree. The main disadvantage of our theory is that homocystinuria causes mental retardation and Akhenaten was, most probably, of normal intelligence. However Mudd et al. reported that IQ of untreated homocysteinuric patient was between 10 and 138 (median 64)¹⁵. Second question is; is it possible for so ill couple (both suffering of homocystinuria to have six children? According to Mudd it is not uncommon that untreated women who suffer from homocystinuria have a normal pregnancy and untreated men can have children¹⁵. The main advantage of our theory is that it is the only one that could actually be tested in the near future. According to Holms there are plans to study DNA of Tutankhamon²². If they succeed, what could his DNA reveal to us about Akhenaten's disease? In case of Marfan syndrome probably nothing. Tutankhamon was, most probably, unaffected; this means that he had not inherited a gene for Marfan syndrome from his father and this theory could not be neither confirmed nor rejected. The same case is for Klinefelter syndrome,

Froelich's syndrome, schistosomiasis, myotonic dystrophy and elephantiasis. Contrary to this, in case of our hypothesis this DNA analysis would reveal a lot. If Akhenaten had homocystinuria, then Tutankhamon, his son, is bound to have one recessive gene for homocystinuria.

If this gene would be found our theory would be confirmed. The most accurate results would be from Akhenaten's mummy, but there is not much hope that it will be ever found.

REFERENCES

1. KUHRT A, The Ancient Near East c. 3000–330 BC (Routledge, New York, 1997).
2. URANIĆ I, Stari Egipat (Školska knjiga, Zagreb, 2002).
3. BURRIDGE A, Biblical Archaeologist, 59 (1996) 127.
4. VRHOVAC B, Interna medicina (Naklada Ljevak, Zagreb, 2003).
5. ROBBINS SL, KUMAR V, COTRAN RS, Osnove patologije (Školska knjiga, Zagreb, 2000).
6. ROBINSON PN, BOOMS P, Cell Mol Life Sci, 58 (2001) 1698–707.
7. GORDON AM, J Ky Med Assoc, 60 (1962) 249.
8. SOTOS JG, The Physical Lincoln: Finding the Genetic Cause of Abraham Lincoln's Height, Homeliness, Pseudo-Depression, and Imminent Cancer Death (Mt. Vernon Book Systems, Mount Vernon, 2008).
9. ALDRED C, Akhenaten King of Egypt (Thames and Hudson, London, 1991).
10. PAULSHOCK BZ, JAMA, 244 (1980) 160.
11. GHALIOUNGUI P, Health and Healing in Ancient Egypt (Centre of Documentation and Studies on Ancient Egypt, Cairo, 1965).
12. CATTAINO G, VICARIO L, Eur Neurol, 41 (1999) 59.
13. VELIKOVSKY I, Oedipus And Akhnaton, Myth And History (Doubleday & Company Inc, New York, 1960).
14. MUDD SH, LEVY HL, SKOVBY F, Disorders of transsulfuration, In: SCRIVER CHR, BEAUDET AL, SLY WS, VALLE D (Eds) The metabolic and molecular bases of inherited disease (McGraw-Hill, New York, 1995).
15. MUDD SH, SKOVBY F, LEVY HL, PETTIGREW KD, WILCKEN B, PYERITZ RE, ANDRIA G, BOERS GH, BROMBERG IL, CERONE R, FOWLER B, GRÖBE H, SCHMIDT H, SCHWEITZER L, Am J Hum Genet, 37 (1985).
16. ABBOTT MH, FOLSTEIN SE, ABBEY H, PYERITZ RE, Am J Med Genet, 26 (1987) 959.
17. SHAW I (Ed) The Oxford History of Ancient Egypt (Oxford University Press, New York, 2000).
18. SHULZ R, SEIDEL M, Egypt The world of the Pharaohs (American University in Cairo press, Cairo, 2001).
19. CRUYSBERG JR, BOERS GH, TRIJBELS JM, DEUTMAN AF, BMJ, 313 (1996) 1037.
20. BRENTON DP, Postgrad Med J, 53 (1977) 488.
21. FRYER RH, WILSON BD, GUBLER DB, FITZGERALD LA, RODGERS GM, Arterioscler Thromb, 13 (1993) 1327.
22. HOLM S, Theor Med Bioeth, 22 (2001) 437.

M. Čavka

Department of Diagnostic and Interventional Radiology, University Hospital Dubrava, 6 Av. Gojka Šuška, 10000 Zagreb, Croatia
e-mail: micavka@globalnet.hr

HOMOCISTINURIJA, MOGUĆE RJEŠENJE EHNATONOVE TAJNE

SAŽETAK

Faraon Amenofis IV. (Amenhotep IV.), poznatiji kao Ehnaton, najtajnovitija je osoba u egipatskoj povijesti. Ovaj revolucionarni vladar 18. dinastije proveo je vjersku revoluciju i postavio nove standarde u umjetnosti. Ostaje nejasno je li groteskni prikaz njega i njegove obitelji samo umjetnički odmak od staroegipatskog kanona ili vrhunski paleopatološki priručnik. Da bi se objasnio njegov izgled, dosad je predloženo nekoliko bolesti od kojih je mogao bolovati, ali ni jedna nije u potpunosti prihvatljiva. Mi predlažemo novu bolest; homocistinuriju – manjak cistationin-sintaze. Zaključujemo da u usporedbi sa dosad najboljom teorijom – da je Ehnaton bolovao od Marfanovog sindroma, naša teorija jednako dobro objašnjava njegov izgled, ali bolje objašnjava zahvaćenost odnosno nezahvaćenost njegovih rođaka. Ovo je jedina teorija o Ehnatonovoj bolesti koja bi mogla biti provjerena u bliskoj budućnosti.