

Dual kidney transplantation: case report

Vidas, Željko; Kocman, Branislav; Knotek, Mladen; Škegro, Dinko

Source / Izvornik: **Collegium Antropologicum, 2010, 34, 697 - 700**

Journal article, Published version

Rad u časopisu, Objavljena verzija rada (izdavačev PDF)

Permanent link / Trajna poveznica: <https://um.nsk.hr/um:nbn:hr:105:227828>

Rights / Prava: [In copyright](#) / [Zaštićeno autorskim pravom.](#)

Download date / Datum preuzimanja: **2024-07-19**



Repository / Repozitorij:

[Dr Med - University of Zagreb School of Medicine
Digital Repository](#)



Dual Kidney Transplantation: Case Report

Željko Vidas¹, Branislav Koeman², Mladen Knotek^{3,4} and Dinko Škegro³

¹ Division of Urology, »Mercur« University Hospital, Zagreb, Croatia

² Department of Surgery, »Mercur« University Hospital, Zagreb, Croatia

³ Division of Nephrology, »Mercur« University Hospital, Zagreb, Croatia

⁴ Zagreb University, School of Medicine, Zagreb, Croatia

ABSTRACT

Chronic shortage of kidney transplants worldwide has led to the use of organs from so called marginal or borderline donors, now termed »expanded-criteria donors«. There has been an emerging practice of dual kidney transplantation (DKT) to compensate for sub optimal nephron mass of such kidneys. We performed DKT in »Mercur« University Hospital in August 2005. The donor was a 72-year old female with a history of long-term hypertension, aneurysm of the posterior cerebral artery, cerebrovascular insult (CVI), and with normal creatinine values and kidney function at the time of explantation. Initial biopsy of donor kidneys revealed acute tubular damage, with connective changes in 22% and 11% of glomeruli in the left and the right kidney, respectively. The recipient was a 60-year old male diagnosed with the IgA nephropathy on the last biopsy in 1999, and on dialysis since November 2003. Postoperative course was uneventful without any surgical complications. A triple immunosuppressive protocol was used. On follow-up ultrasonography 4 years posttransplantation both kidneys appeared of normal size and parenchymal pattern and with no signs of dilatation of the canal system, and color Doppler examination demonstrated normal flow in both kidneys. In conclusion, the use of DKT, ie. donors by the expanded-criteria will continue to increase, and further studies of the results will, with no doubt, support this method.

Key words: dual kidney transplantation, marginal donor, extended-criteria donor

Introduction

The number of patients awaiting a suitable kidney in Croatia reaches 800 each year. With approximately one hundred kidney transplantations being performed per year, many of the patients on the waiting list will die before transplantation. Organ shortage incited the development of new strategies to expand the pool of organ donors and to improve access to cadaveric kidneys, but despite the efforts this number remained fixed and insufficient to meet ever-increasing demands. This necessarily results in longer waiting times and more deaths of patients who wait for a transplant on dialysis¹. Chronic shortage of organs for transplantation worldwide has led to the use of so-called marginal or borderline donors, now termed expanded-criteria donor«. This approach basically consists in implantation of two kidneys in order to theoretically double the nephron mass and so to compensate for inadequacies anticipated with single kidney transplantation (SKT)^{2,3}. There are few studies on this in the literature. We reviewed the policies of other centers

and identified the most common criteria for dual kidney transplantation (DKT). First, the most usual donor age for DKT ranges 55–75 years⁴. Second, donors had a creatinine clearance 50–70 mL/min. Third, cold ischemia time should not exceed 24 hours^{5,6}. Fourth, DKT was only performed with the kidneys that were refused as single organs by all local centers. There is another separate issue: preimplantation biopsy (PIB)⁷. There are studies reporting allocation of kidneys for DKT with 15–20% glomerulosclerosis on PIB, and in most cases PIB helps discard the kidneys with severe histopathologic changes, while kidneys with minimum histological alterations can be utilized for SKT, as a means to prevent decrease in the organ donor pool^{8,9}. Most studies of outcomes after DKT report a poorer graft survival of 7% and 15% at one and three years posttransplant, respectively¹. Based on all parameters mentioned above, the transplantation team of the »Mercur« University Hospital in August 2005 performed the first DKT in Croatia.

Case Report

The donor was a 72-year old female with a history of long-standing hypertension, aneurysm of the posterior cerebral artery, and cerebrovascular insult (CVI). The patient had normal creatinine value and kidney function at the time of explantation. Donated kidneys were initially biopsied.

The left kidney (implanted proximally): section of the renal parenchyma of eight mm in diameter was cut serially and stained with hemalaun eosin, PAS, Masson's Trichrome and Jones stain. Thirty seven glomeruli were found per cross-section. Connective changes were found in 22% of glomeruli. The remaining glomeruli appeared morphologically normal. Tubuli showed extensive loss of microvilli with localized dilatation and necrosis of individual epithelial cells. Hyaline cylinders were present in some tubuli, desquamated epithelial cells in others. Localized granular cylinders were only visible. Larger blood vessels only demonstrated mild fibrointimal thickening, while arterioles and smaller arteries were of morphologically normal appearance. The finding was consistent with acute tubular damage with 22% glomeruli with connective changes. Mild arteriosclerosis was also present. No significant interstitial fibrosis or tubular atrophy was found.

The right kidney (implanted distally): renal parenchymal section of maximum 5 mm in diameter was cut serially and stained in the same way. Twenty seven glomeruli were found per cross-section. Eleven percent of glomeruli were found with complete connective changes. The remaining glomeruli showed normal morphology. In tubuli extensive necrosis of the epithelial cells was present with numerous granular cylinders. One tiny focus of interstitial fibrosis and tubular atrophy was visible. Blood vessels showed normal morphology. The finding corresponded to acute tubular damage, which was more severe than that found in the left kidney.

The recipient was a 60-year old male who had been under nephrological follow-up for twenty years prior to the transplant. The last biopsy, performed in 1999, was suggestive of IgA nephropathy. The patient had been on hemodialysis since November 2003 and had been suffering from hypertension from the beginning of his kidney disease. On ultrasound examination cholelithiasis was found. In 2004, the patient was treated for a milder form of antral ulcer.

The surgical procedure begins with a lateral incision above the right iliac fossa. The right iliac artery and vein, right external iliac vein and distal parts of the common iliac arteries and veins are retroperitoneally exposed and prepared. The proximally placed kidney is implanted first. The renal artery is anastomosed end-to-side to recipient common iliac artery and the renal vein is anastomosed to the common iliac vein with Prolene (5–0) sutures. After revascularization, clamps are placed on the external iliac artery and vein, and anastomoses of the distally placed kidney are stapled using the same technique. Following completion of vascular anastomoses,

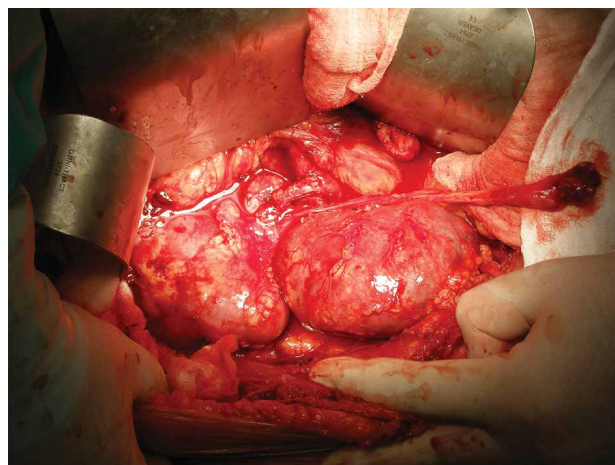


Fig. 1. Position (proximally and distally placed kidney) immediately following completion of stapling of vascular anastomoses. In the proximally placed kidney, anastomosis of the renal artery to the common iliac artery and the proximal kidney ureter are seen.

separate ureteroneocystostomies 3 cm apart are performed according to the Lich-Gregoir technique, using double JJ stents.

We used the triple immunosuppression protocol: cyclosporine, prednisone, and mycophenolate. Postoperative course was uneventful. There were no surgical complications in our patient. Kidney allograft function was presented immediately posttransplant, diuresis gradually increased about one liter per day, and no renal replacement therapy was necessary. Anemia was corrected during the patient's intensive care unit (ICU) stay. On the day 5 posttransplant the patient was transferred from the ICU to the ward where he stayed for the next 30 days. The patient was dismissed from hospital with normal diuresis and the creatinine value of 385. On further follow-ups from 4 to 6 months after transplantation creatinine values ranged 154–201 $\mu\text{mol/L}$. An ultrasonography of the transplanted kidneys 4 years following transplantation showed the proximal kidney 104 mm in size, kidney parenchyma 13–15 mm in width, and the distal kidney 98 mm in size and parenchyma 14–15 mm in width. On both kidneys visible cortico-medullary differentiation and the renal parenchyma of slightly greater echogenicity. No conclusive signs of kidney stones were detected. No dilatation of the kidney canal system was found. Color Doppler ultrasound examination detected flow through the renal artery and vein and through their intrarenal branches. In the distal kidney, renal arterial flow velocity was cca 0.7 m/s, the visualization of the proximal renal artery failed due to meteorism. The spectra of frequencies in the intrarenal branches were of normal appearance. The average resistance index (RI) in the proximal kidney was 0.60, in the distal kidney 0.70. Comment: Normal blood flow in both kidneys. Results of laboratory tests: white blood cell count (WBC) $6.07 \times 10^9/\text{L}$, red blood cell count (RBC) $4.7 \times 10^{12}/\text{L}$, hemoglobin (Hb) 136 g/L, hematocrit (Hct) 0.418 L/L, mean cell volume

(MCV) 88.4 fL, mean cell hemoglobin (MCH) 28.8 pg, mean cell hemoglobin concentration (MCHC) 325 g/L, platelet count (Plt) $199 \times 10^9/L$, potassium 4.3 mmol/L, blood glucose 4.5 mmol/L, urea 14.8 mmol/L, creatinine 194 mmol/L, urate 471 mmol/L, C-reactive protein (CRP) 6.0 mg/L, cyclosporine /FPIA/ 76 $\mu\text{g/L}$ and mycophenolate /EMIT/ 8.8 $\mu\text{mol/L}$.

Discussion and Conclusion

The increasing demand for organ transplants causes many transplant centers to accept organs from marginal donors, now termed »expanded-criteria donors«. An additional rationale for dual kidney transplantation has been provided by recent studies which reported better survival rates for patients who received a DKT with marginal donor kidneys than for patients remaining on dialysis. DKTs can be transplanted with each allograft implanted in separate iliac fossae (bilateral) or separately with both allografts placed in one iliac fossa (unilateral), or they can be transplanted en-bloc¹⁰. Observing the fact that in studies published so far no one surgical approach has proved definitely more appropriate, and bilateral kidney placement may later compromise the anatomical space for possible future transplantations, we opted for separate transplantation and positioned both kidneys in the right iliac fossa. Implantation of the ureters can be performed by separate or conjoined ureteroneocystostomies¹¹. We anastomosed the ureters to the bladder via separate ureteroneocystostomies. Because the proximally implanted kidney is considerably more distant in location to the urinary bladder than the distally implanted kidney, when deciding on which kidney is to be placed proximally the one should be selected whose ureter remained longer after explantation.

There is a paucity of surgical complication data on DKT compared with SKT^{12,13}. In addition to somewhat more frequent incidence of lymphocele and bleeding, particularly in bilateral implantations, a significantly higher rate of deep venous thrombosis, infections, strictures of ureterovesical anastomosis and ureteral obstruction, especially in conjoined ureteroneostomies, have been reported in DKT compared with SKT. In our experience, the unilateral placement of DKT reduced the surgical injury, reducing postoperative complications.

The use of immunosuppressive protocols varies in individual centers¹⁴. We followed standard triple cyclosporine-based immunosuppression which is usually used. Calcineurin-inhibitor (CNI) free protocols are advocated by some authors due to CNI-induced nephrotoxicity. In most studies no significantly improved graft function or survival was observed with a calcineurin-inhibitor-free immunosuppression regimen compared with cyclosporine-based immunosuppression.

In most studies DKT has been reported to be associated with a considerably higher rate of primary transplant nonfunction and 7% and 15% poorer graft survival after one and three years posttransplant, respectively, when compared with single kidney transplantation¹⁵. Notably, however, in donors 55 years of age or older DKT resulted in outcomes similar to those reported for SKT. Therefore, it can be inferred that DKT and SKT are accompanied by comparable long-term results. In conclusion, developing more refined criteria for matching marginal donors to recipients may be important in order to reduce the risk for patients to a reasonable level. We believe that organs from »expanded-criteria donors« and the practice of DKT will continue to be increasingly used, and that further studies of the results will, no doubt, justify this method.

REFERENCES

1. ALFREY EJ, BOISSY AR, LERENR SM, Transplantation, 75 (2003) 1232. — 2. JOHNSON LB, DUO PC, DAFOE DC, DRACHENBER CB, SCHWEITZER EJ, ALFREY EJ, RIDGE LA, SALVATIERRA P, PAPANIMITRIOU JC, MERGNER WJ, BARTLETT ST, Transplantation, 61 (1996) 1261. — 3. OJO AO, HANSON JA, MEIER-KRIESCHNE H, OKECHUKWU CN, WOLFE RA, LEICHTMAN AB, AGODOA LY, KAPLAN B, PORT FK, J Am Soc Nephrol, 12 (2001) 589. — 4. KASISKE BL, CANGRO CB, HARIHARAN S, HRICIK DE, KERMAN RH, ROTH D, RUSH DN, VAZQUEZ MA, WEIR MR, AMERICAN SOCIETY OF TRANSPLANTATION, Am J Transplant, 1 (2001) 1. — 5. METZGER RA, DELMONICO FL, FENG S, PORT FK, WYNN JJ, MERION RM, Am J Transplant, 4 (2003) 114. — 6. SALAHUDEEN A, HAIDER N, MAY W, Kidney Int, 65 (2004) 713. — 7. RANDHAVA PS, MINERVINI MI, LOMBARDENO M, DUGUESNOY R, FUNG J, SHAPIRO R, JORDAN M, VIVAS C, SCANTLEBURY V, DEMETRIS A, Transplantation, 69 (2000) 1352. — 8. REMUZZI G, GRINIYO J, RUGENNETI P, BEATINI M, COLE EH, MILFORD EL, BRENNER BM, J Am Soc Nephrol, 10 (1999) 2591. — 9. PORT FK, BRAGG-GRESHAM JL, METZGER RA, DYKSTRA DM, GILLESPIE BW, YOUNG EW, DELMONICO FL, WYNN JJ, MERION RM, WOLFE RA, HELD PJ, Transplantation, 74 (2002) 1281. — 10. SINGER J, GRITSCH HA, ROSENTHAL JT, The transplant operation and its surgical complications. In: DANOVITCH GM (Ed) Handbook of kidney transplantation (Lippincott, Philadelphia, 2005). — 11. BARRY MJ, HATCH DA, J Urol, 134 (1985) 249. — 12. FISHMAN JA, RUBIN RH, N Engl J Med, 338 (1998) 1741. 13. NARGUND VEH, CARNSTON D, Transplant Rev, 10 (1996) 10. — 14. ANIL KUMAR MS, IRFAN SEED M, RANGANNA K, MALAT G, SUSTENTO-REODICA N, KUMAR AM, MEYERS WC, Transpl Immunol, 20 (2008) 32. — 15. TAN JC, ALFREY JE, DAFOE CD, MILLAN TM, SCNADLING DJ, Transplantation, 78 (2004) 692.

Ž. Vidas

Division of Urology, »Mercur« University Hospital, Zajčeva 19, Zagreb, Croatia
e-mail: zeljko.vidas@zg.t-com.hr

DVOSTRUKA TRANSPLANTACIJA BUBREGA

SAŽETAK

Kronični nedostatak bubrega za transplantaciju u svijetu doveo je do uzimanja organa od takozvanih graničnih ili marginalnih donora što je kasnije dobilo naziv »donor prema proširenim kriterijima«. U Kliničkoj bolnici Merkur, u kolovozu 2005. godine napravljena je dvostruka transplantacija bubrega. Donor je bila 72-godišnja bolesnica s anamnezom dugogodišnje hipertenzije, aneurizme stražnje cerebralne arterije, cerebralnim vaskularnim inzultom (CVI) te urednim nalazima kreatinina i funkcijom bubrega kod eksplantacije. Učinjena je nulta biopsija donorskih bubrega gdje je na lijevom bubregu nalaz odgovarao akutnom tubularnom oštećenju uz 22% vezivno promijenjenih glomerula. Na desnom bubregu nalaz je odgovarao akutnom tubularnom oštećenju uz 11% vezivno promijenjenih glomerula. Primatelj je bio muška osoba stara 60 godina kod koje je posljednja biopsija učinjena 1999. godine pokazala IgA nefropatiju te je bio na programu hemodijalize od studenog 2003. godine. Postoperacijski tijek prošao je uredno bez ijedne kirurške komplikacije. Korišten je protokol trostruke imunosupresije. Na kontrolnom pregledu 4 godine nakon transplantacije, ultrazvučnim pregledom utvrdi se normalna veličina oba bubrega s održanim parenhimom bez znakova dilatacije kanalnog sustava te uredan dopler protok kroz oba bubrega. Možemo zaključiti da će broj dvostrukih transplantacija bubrega, odnosno korištenje donora prema proširenim kriterijima biti sve veći, a daljnje praćenje rezultata zasigurno opravdati ovu metodu.