

Pulmonary valve papillary fibroelastoma diagnosed by echocardiography: a case report

Biočić, Stanko; Pukšić, Silva; Vincelj, Josip; Đurašević, Željko; Sutlić, Željko; Manojlović, Spomenka

Source / Izvornik: **European Journal of Echocardiography, 2009, 10, 726 - 728**

Journal article, Accepted version

Rad u časopisu, Završna verzija rukopisa prihvaćena za objavljivanje (postprint)

<https://doi.org/10.1093/ejechoard/jep059>

Permanent link / Trajna poveznica: <https://urn.nsk.hr/urn:nbn:hr:105:412487>

Rights / Prava: [In copyright](#) / [Zaštićeno autorskim pravom.](#)

Download date / Datum preuzimanja: **2025-02-18**



Repository / Repozitorij:

[Dr Med - University of Zagreb School of Medicine
Digital Repository](#)





Središnja medicinska knjižnica

Biočić S., Pukšić S., Vincelj J., Đurašević Ž., Sutlić Ž., Manojlović S.
(2009) *Pulmonary valve papillary fibroelastoma diagnosed by*
***echocardiography: a case report.* European Journal of**
Echocardiography, 10 (5). pp. 726-8. ISSN 1525-2167

<http://ejechocard.oxfordjournals.org>

<http://dx.doi.org/10.1093/ejechocard/jep059>

<http://medlib.mef.hr/884>

University of Zagreb Medical School Repository

<http://medlib.mef.hr/>

**PULMONARY VALVE PAPPILARY FIBROELASTOMA DIAGNOSED BY
ECHOCARDIOGRAPHY: A CASE REPORT**

**Stanko Biočić (1), Silva Pukšić (1)*, Josip Vincelj (1), Željko Đurašević (1), Željko Sutlić
(2), Spomenka Manojlović (3)**

**¹ Department of Cardiology, Clinical Hospital Dubrava, Av. Gojka Šuška 6, 10 000
Zagreb, Croatia; ² Department of Cardiac Surgery, Clinical Hospital Dubrava,
Av.Gojka Šuška 6, 10 000 Zagreb, Croatia; ³ Department of Pathology, Clinical Hospital
Dubrava, Av.Gojka Šuška 6, 10 000 Zagreb, Croatia**

***Corresponding author: Silva Pukšić, Department of Cardiology, Clinical Hospital
Dubrava, Av.Gojka Šuška 6, 10 000 Zagreb, Croatia**

Email: silva.puksic@vz.t-com.hr

Telephone: +385-98-9365-148

Fax: +385-1-2902-700

Here are the free-access links to your online article:

Abstract:

[http://ejechocard.oxfordjournals.org/cgi/content/abstract/jep059?
ijkey=HtvWzzEXIZWDYIL&keytype=ref](http://ejechocard.oxfordjournals.org/cgi/content/abstract/jep059?ijkey=HtvWzzEXIZWDYIL&keytype=ref)

Full Text:

[http://ejechocard.oxfordjournals.org/cgi/content/full/jep059?
ijkey=HtvWzzEXIZWDYIL&keytype=ref](http://ejechocard.oxfordjournals.org/cgi/content/full/jep059?ijkey=HtvWzzEXIZWDYIL&keytype=ref)

PDF:

[http://ejechocard.oxfordjournals.org/cgi/reprint/jep059?
ijkey=HtvWzzEXIZWDYIL&keytype=ref](http://ejechocard.oxfordjournals.org/cgi/reprint/jep059?ijkey=HtvWzzEXIZWDYIL&keytype=ref)

ABSTRACT:

Papillary fibroelastomas (PFEs) are rare cardiac valve tumours with reported incidence of <0.03% according to autopsy studies. Among them pulmonary valve PFEs are extremely rare. With wider use of echocardiography, they are being increasingly recognised premortem. We describe a case of a 32-year-old Caucasian woman with papillary fibroelastoma of pulmonic valve diagnosed by echocardiography. The patient underwent surgery with complete tumour resection and total preservation of valve function. This case report discusses diagnostics of PFEs, their characteristic echocardiographic and histological features, possible complications and suggests treatment options in this rare cardiac tumour.

KEY WORDS: papillary fibroelastoma, pulmonary valve, echocardiography

CASE REPORT

Introduction

Primary cardiac tumours are rare with an incidence of 0.0017%-0.33% according to autopsy studies [1]. The most common are myxomas (30%), followed by lipomas (10%) and papillary fibroelastomas (PFEs) (8%) [2]. Papillary fibroelastomas typically originate from valve endocardium of left-sided heart valves (95%), whereas pulmonary valve involvement is rare comprising only 8% of the cases [3]. According to our knowledge, only 12 case reports of pulmonary PFEs, diagnosed by echocardiography, have so far been reported in the literature.

Case presentation

A 32-year-old Caucasian woman with symptoms of intermittent palpitations was referred for echocardiography. She had no history of chest pain, dyspnoea or unexplained fever. Physical examination and laboratory values were unremarkable. On transthoracic echocardiography suspected tumour mass of the pulmonary valve was visualized. Transoesophageal echocardiography, subsequently performed for detailed evaluation, confirmed an echogenic tumour measuring 10 x 11 mm in diameter attached with a thin stalk to the right leaflet of the pulmonary valve. The mass was highly mobile and prolapsed across the pulmonary valve orifice (Figure 1). The pulmonary valve itself was functionally normal with no evidence for regurgitation or stenosis. The patient was referred to surgery. A transverse arteriotomy of the main pulmonary trunk was made slightly above the pulmonary valve revealing a translucent, yellowish pedunculated tumour of the right leaflet. The tumour was completely excised with minimal dissection of the valve.

In gross pathologic examination, the tumour measured 1.6 cm in longest diameter and was comprised of multiple strand-like projections. In histological examination, each projection was composed of avascular connective tissue surrounded by a single layer of endothelial cells (Figure 2). The diagnosis of PFE was confirmed. Postoperative

echocardiogram revealed no signs of pulmonary valve dysfunction. The patient was well on further hospital stay and on follow-up.

Discussion

The valvular surface is the predominant location of the PFEs, although they can be found on papillary muscles, chordae tendineae, and endocardium [4]. The differential diagnosis includes other tumours (myxomas, lipomas or valve strands), thrombi and bacterial vegetations [5]. According to specific echocardiographic characteristics, they are most often solitary, usually < 1.5 cm in diameter, arising from the midportion of valve leaflet, often pedunculated and usually mobile. They have a refractive appearance with areas of echolucency within the tumour and a characteristic stippled edge [6,7]. Though they are benign in nature and rarely cause valvular dysfunction, [4] they can cause serious complications such as systemic and pulmonary embolism [2]. The tumour surface, comprising of multiple projections, makes it highly friable as well as susceptible for clot formation [4-6]. The most common clinical presentation in general is transient ischaemic attack or stroke resulting from cerebral embolization [3]. Although surgery is advocated for left-sided tumours, much less is known on management of right-sided tumours. They are mostly asymptomatic but can be related to complications such as pulmonary embolism or paradoxical embolism in the presence of patent foramen ovale [3,8]. Our patient had no previously proven pulmonary embolism but her symptoms suggested possible chronic pulmonary microembolization from the tumour. The tumour was also extremely mobile on echocardiographic examination which is considered the only independent predictor of PFE-related death or nonfatal embolization [3]. That is why surgical excision is advocated even in asymptomatic patients [2,3]. The use of long-term anticoagulation, as another option, seems more appropriate for elderly patients with contraindications to surgery. Surgical approach

involves a relatively simple excision of the mass with excellent short- and long-term prognosis after the operation [3,8,9]. We decided to operate our patient based on these considerations. In the past, PFEs were usually detected as autopsy findings, whereas today, they are more commonly diagnosed pre-mortem with the advances of echocardiographic examination. To our knowledge, our patient is so far the youngest patient reported with PFE of the pulmonary valve diagnosed by echocardiography and successfully managed with cardiac surgery.

References

1. Howard RA, Aldea GS, Shapira OM, Kasznica JM, Davidoff R. Papillary fibroelastoma: increasing recognition of a surgical disease. *Ann Thorac Surg* 1999;68(5):1881-5.
2. Daccarett M, Burke P, Saba S. Incidental finding of a large pulmonary valve fibroelastoma: a case report. *Eur J Echocardiogr* 2006;7(3):253-6.
3. Gowda RM, Khan IA, Nair CK, Mehta NJ, Vasavada BC, Sacchi TJ. Cardiac papillary fibroelastoma: A comprehensive analysis of 725 cases. *Am Heart J* 2003; 146:404-10.
4. Costa MJ, Makaryus AN, Rosman DR. A rare case of a cardiac papillary fibroelastoma of the pulmonary valve diagnosed by echocardiography. *Int J Cardiovasc Imaging* 2006;22(2):199-203.
5. Saad RS, Galvis CO, Bshara W, Liddicoat J, Dabbs DJ. Pulmonary valve papillary fibroelastoma: a case report and review of the literature. *Arch Pathol Lab Med* 2001;125(7):933-4.
6. Daveron E, Jain N, Kelley GP, Luer WH, Fermin C, Helmcke F et al. Papillary fibroelastoma and Lambl's excrescences: Echocardiographic diagnosis and differential diagnosis. *Echocardiography* 2005;22(5):461-3.
7. Klarich KW, Enriquez-Sarano M, Gura GM, Edwards WD, Tajik AJ, Seward JB. Papillary fibroelastoma: echocardiographic characteristics for diagnosis and pathologic correlation. *J Am Coll Cardiol* 1997;30(3):784-90.
8. Ngaage DL, Mullany CJ, Daly RC, Dearani JA, Edwards WD, Tazelaar HD et al. Surgical treatment of cardiac papillary fibroelastoma: a single center experience with eighty-eight patients. *Ann Thorac Surg* 2005;80(5):1712-18.
9. Yopp AC, Vaynblat M, Cunningham JN Jr, Lazzaro RS. Cardiac valve papillary fibroelastoma: surgical excision for revealed or potential embolization. *J Card Surg* 2007;22(1):72-3.

Figure legends

Figure 1: Transoesophageal echo in short axis view at 61° showing a tumour (TM) of the pulmonary valve; RA (right atrium), RV (right ventricle), PA (pulmonary artery), RVOT (right ventricular outflow tract).

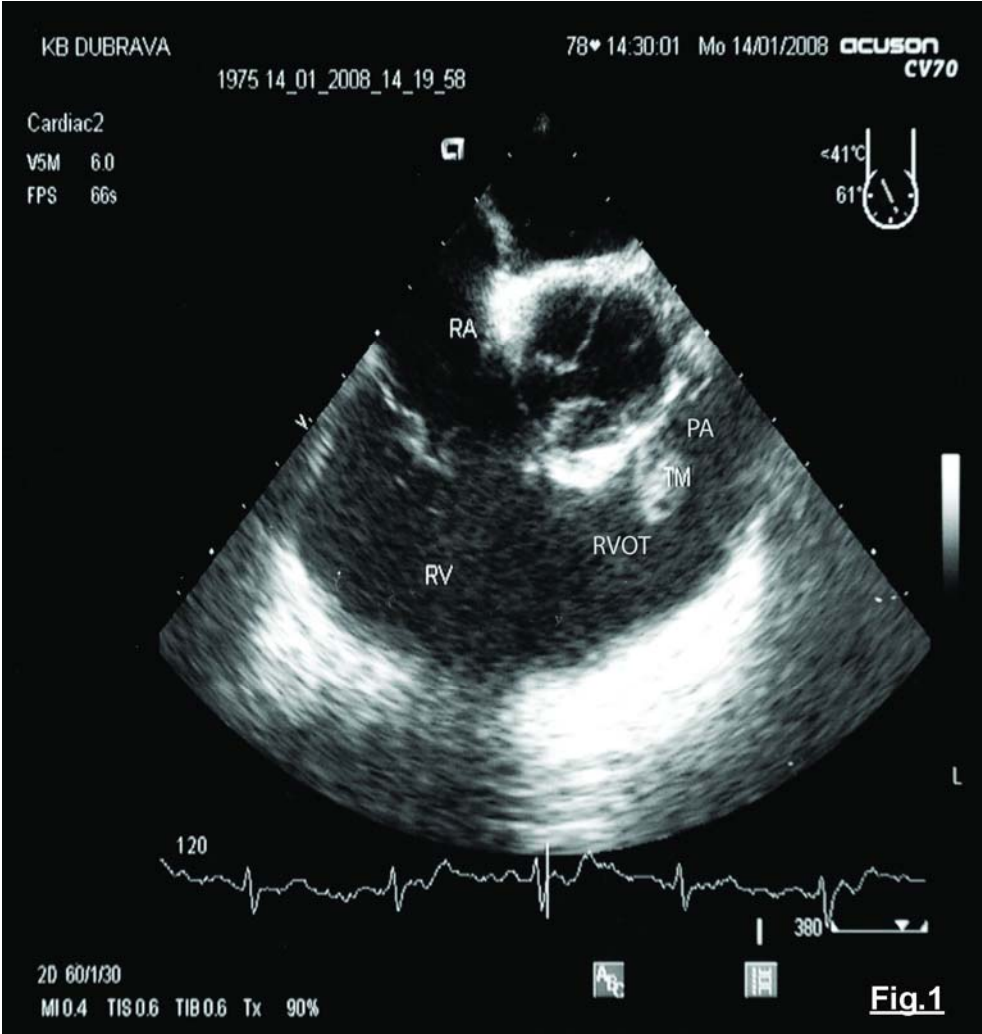


Figure 2: Histopathological specimen of the tumour showing multiple avascular hyaline fronds are lined by flattened endothelial cells (H&E stain, x 100).

