

Subcutaneous panniculitis-like T-cell lymphoma in a 19 month-old boy: a case report

Rajić, Ljubica; Bilić, Ernest; Femenić, Ranka; Meštrović, Daniel; Ilić, Ivana; Lasan-Trčić, Ružica; Dubravčić, Klara; Husar, Karmela; Kardum-Skelin, Ika; Tešović, Goran; ...

Source / Izvornik: **Collegium Antropologicum, 2010, 34, 679 - 682**

Journal article, Published version

Rad u časopisu, Objavljena verzija rada (izdavačev PDF)

Permanent link / Trajna poveznica: <https://um.nsk.hr/um:nbn:hr:105:378257>

Rights / Prava: [In copyright](#)/[Zaštićeno autorskim pravom.](#)

Download date / Datum preuzimanja: **2024-07-14**



Repository / Repozitorij:

[Dr Med - University of Zagreb School of Medicine Digital Repository](#)



Subcutaneous Panniculitis-like T-cell Lymphoma in a 19 Month-old Boy: A Case Report

Ljubica Rajić^{1,9}, Ernest Bilić^{1,9}, Ranka Femenić¹, Daniel Meštrović², Ivana Ilić³, Ružica Lasan-Trčević⁴, Klara Dubravčić⁵, Karmela Husar⁶, Ika Kardum-Skelin^{7,9}, Goran Tešović⁸, Zdravka Čulig⁸ and Josip Konja^{1,9}

¹ Department of Haematology and Oncology, Pediatric Clinic, Zagreb University Hospital Center, Zagreb, Croatia

² Department of Pediatrics, Karlovac General Hospital, Karlovac, Croatia

³ Department of Pathology, Zagreb University Hospital Center, Zagreb, Croatia

⁴ Division of Cytogenetics, Pediatric Clinic, Zagreb University Hospital Center, Zagreb, Croatia

⁵ Department of Clinical Laboratory Diagnostics, Zagreb University Hospital Center, Zagreb, Croatia

⁶ Dermatovenerologic Clinic, Zagreb University Hospital Center, Zagreb, Croatia

⁷ Department of Clinical Cytology, »Merkur« University Hospital, Zagreb, Croatia

⁸ Clinic for Infectious Diseases, Zagreb, Croatia

⁹ Zagreb University, School of Medicine, Zagreb, Croatia

ABSTRACT

Subcutaneous panniculitis-like T-cell lymphoma (SPTCL) is a rare type of T-cell lymphoma of CD3+CD8+ phenotype characterized by deep-seated skin nodules or plaques mimicking panniculitis, a result of neoplastic lymphocytes infiltrating the subcutaneous fatty tissue. We present a case of a 19-month year old boy with SPTCL diagnosed and successfully treated in our institution. Disease first presented with symptoms of high fever and painful erythematous nodule located below the umbilicus. Later on the infiltrates appeared on the face, legs, arms and the back of the body. As the most decisive in obtaining the diagnosis, skin biopsy showed atypical, small to medium-sized lymphatic cells infiltrating the deeper dermal layers as well as the subcutaneous adipous tissue surrounding the adipocytes. Immunohistochemical analysis showed neoplastic lymphocytes positive for CD2, CD3, CD5, CD7, CD8, Tia-1, granzyme B and perforine, and negative for CD20, CD34, TDT and CD56. No infiltration of blood vessels or epidermis was evident. Specific T-cell lymphomas protocol (EURO-LB 02) was then initiated which resulted with rapid regression of all general and local symptoms. The treatment was completed according to schedule and the child is now, 24 months after the initiation of the treatment, in complete remission.

Key words: subcutaneous panniculitis-like T-cell lymphoma, children, hemophagocytic syndrome, chemotherapy

Introduction

Subcutaneous panniculitis-like T-cell lymphoma (SPTCL) is a rare type of cytotoxic T-cell lymphoma characterized by deep-seated skin nodules or plaques mimicking panniculitis as a result of neoplastic lymphocytes infiltrating subcutaneous fatty tissue. The first described in 1991, by Gonzalez et al.¹, it is now a distinct entity according to the World Health Organization classification regarding its clinical presentation, T-cell recep-

tor phenotype (restricted to only TCR $\alpha\beta$), immunophenotype and prognosis. SPTCL is very rare, making for less than 1% of all non-Hodgkin lymphomas, and presents itself most commonly in young adults, twice as often in females than in males. It is especially rare in childhood². Good clinical prognosis with a 82% 5-year overall survival ratio is described according to one large multicentric retrospective study that included 83 patients

aged 9–79³. Still, there are many uncertainties regarding the optimal therapy and definitive recommendations are still to be defined.

Case Report

We present a case of a 19-month year old boy with subcutaneous panniculitis-like T-lymphoma successfully diagnosed and treated in our clinic. The child was first admitted to a surgical ward at a local general hospital with symptoms of high fever and a painful erythematous nodule located below the umbilicus. The nodule was first documented 12 days prior to admittance during an examination of a right-sided inguinal hernia. Seven days before hospitalization the nodule started growing – turning into a plaque, a change accompanied by occurrence of high fever, measuring up to 40 °C. Following admittance, white blood cell count (WBC) and C-reactive protein (CRP) tests were ordered along with an ultrasound examination – while CRP and WBC were not very convincing (18 mg/L and $5.8 \times 10^9/L$, respectively), the ultrasound showed signs of inflammatory infiltration. A broad-spectrum antibiotic treatment was started, but in spite of it, the plaque became more painful and red, soon measuring 7×5 cm. An incision was made at the third day of hospitalization, but no purulent secretion was noticed.

After two weeks of unsuccessful antibiotic treatment the child, still in refractory high fever, was transferred to the clinic for infectious diseases for further treatment and diagnostic exploration. There, along with the plaque, then measuring 5´5 cm, marginally enlarged cervical lymph nodes and a few smaller infiltrations of the facial skin were noted. A small needle biopsy of an enlarged inguinal lymph node was performed showing only reactive hyperplasia. Fine needle aspiration cytology of facial skin infiltrates showed few large lymphoid cells with lobular »cerebriform« nuclei (Figure 1). The next step was to perform a full-thickness skin biopsy and send the attained specimen further for a full histopathology and immunohistochemical analysis. For that purpose, three weeks after starting the workup, the child was admitted

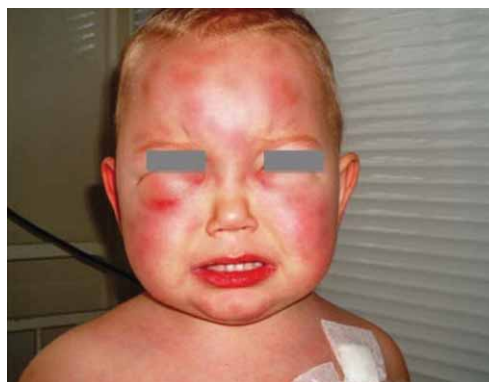

Fig. 2. Erythematous infiltrated plaques and subcutaneous nodules on the face.

to our clinic for further care. At that time the child was in high fever for three whole weeks, he was malaise; his skin was pale and swollen as a result of generalized oedema. Multiple subcutaneous infiltrations were present all over his abdominal wall, face and scalp with new ones appearing on his thighs (Figure 2).

The laboratory check-up upon admittance showed erythrocyte sedimentation rate 7mm/h and CRP 42 mg/dL (range, 0–10 mg/dL). There was marked pancytopenia with WBC $1.8 \times 10^9/L$, hemoglobin 8.1g/dL, and platelet count $67 \times 10^9/L$. Liver enzymes were also increased: alanine aminotransferase was 121 U/L (range, 11–38 U/L), aspartate aminotransferase 149 U/L (range, 12–48 U/L) and γ -glutamyl transferase 62 U/L (range, 11–55 U/L). Serum ferritin and lactate dehydrogenase levels were 2535 $\mu\text{g/L}$ (range, 30–400 $\mu\text{g/L}$) and 1130 U/L (normal <241 U/L), respectively, and total protein 49 g/L (range, 60–78 g/L).

While waiting for the biopsy results, a multi-slice computerized tomography scan (MSCT) of the neck, thorax, abdomen and the pelvis was performed, together with bone marrow aspiration. The MSCT scan showed only bilateral submandibular lymph node enlargement (up to 19 mm in diameter) and splenomegaly (12 cm mea-

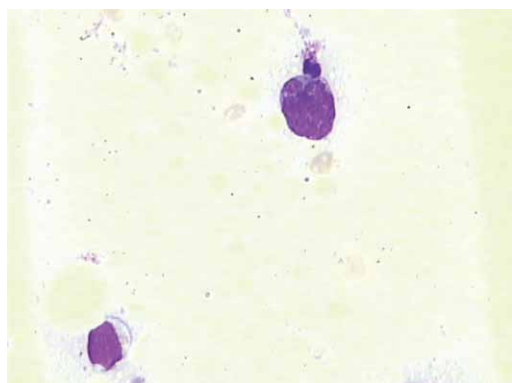


Fig. 1. Fine needle aspiration material of skin lesion stained with May-Grünwald-Giemsa, x1000. Large atypical lymphoid cell with lobular »cerebriform« nucleus.

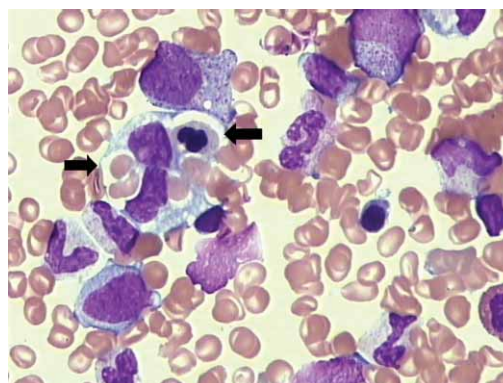


Fig. 3. Bone marrow aspirate smear stained with May-Grünwald-Giemsa, x1000. Arrows show erythrophagocytosis (erythrocytes – left arrow and erythroblast – right arrow) by macrophage.

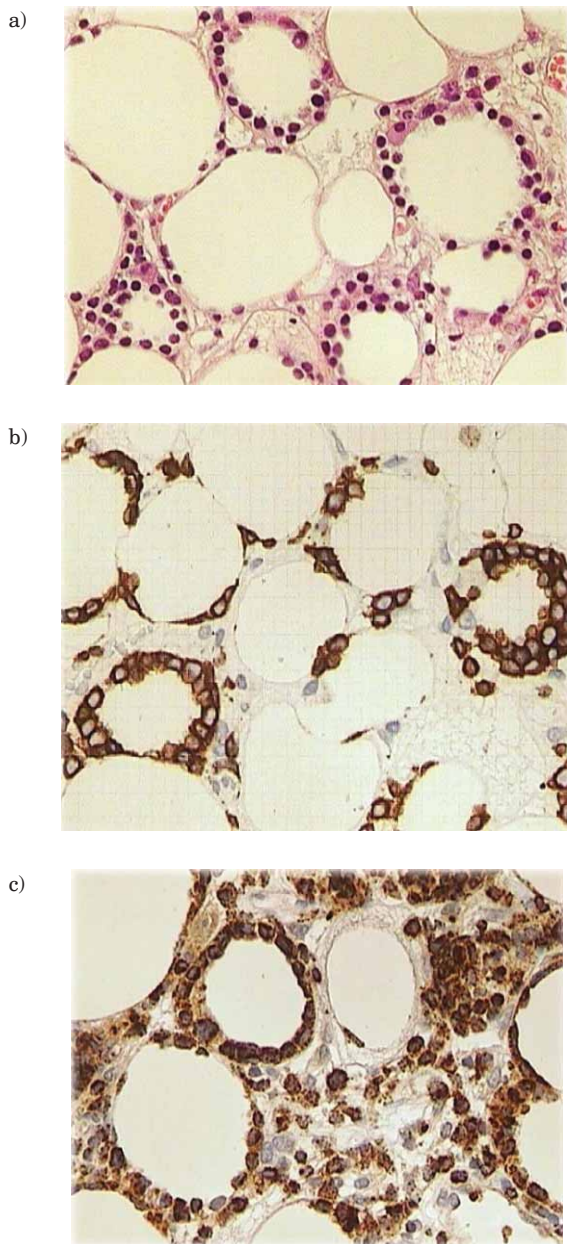


Fig. 4. a. Infiltrate of small lymphocytes rimming the fat cells in the subcutaneous tissue (HE, $\times 400$), b. The neoplastic cells show cytoplasmatic immunostaining for CD8 ($\times 400$), c. Granular TIA-1 cytoplasmatic positivity of tumor cells ($\times 400$).

sured cranio-caudally). Bone marrow cytomorphology revealed marked erythrophagocytosis (Figure 3). Bone marrow immunophenotyping showed no aberrant finding. Cytogenetic analysis of bone marrow aspirate revealed normal karyotype (46, XY). Serologic test for hepatitis A, B and C viruses were negative, specific Epstein-Barr virus IgG was positive, and IgM was negative.

Twenty-nine days after the first symptoms the results of the complete workup were attained and a definite diagnosis of subcutaneous panniculitis-like T-lymphoma was established. Histology showed atypical, small to me-

dium-sized lymphatic cells infiltrating the deeper dermal layers as well as the subcutaneous adipous tissue, surrounding the adipocytes (Figure 4a). In addition, many histiocytes as well as signs of cariorrhesis and focal necrosis were also noted. Immunohistochemistry showed tumor cells expressing CD2, CD3, CD5, CD7, CD8 (Figure 4b), Tia-1 (Figure 4c), granzyme B and perforine, and negative results for CD20, CD34, TDT and CD56.

The patient had evidence of haemophagocytic syndrome with fever, splenomegaly, pancytopenia, increased serum ferritin level and hemophagocytosis on bone marrow examination (Figure 3). We then initiated a specific treatment with EURO-LB02 protocol for lymphoblastic T-lymphomas as follows: cytoreductive pre-phase – pronison; induction protocol – pronison, vincristine, daunorubicine, L-asparaginase in Ia protocol and cyclophosphamide, Ara-C and 6-mercaptopurine in IIb protocol, with intrathecal methotrexate (MTX) according to age. Consolidation protocol M: 4xMTX/5.0 g/m²; re-induction protocol – dexamethason, vincristine, doxorubicine, L-asparaginase in IIa and 6-thioguanine, cyclophosphamide, Ara-C in IIb, and intrathecal MTX according to age. Maintenance therapy included purinethol followed by methotrexate. The chemotherapy was followed by rapid regression of all general and local symptoms.

After 3 days of treatment the child was no longer febrile and the skin lesions became more and more pale eventually completely regressing in two week's time. A control skin biopsy was performed three months after the initiation of treatment showing no elements characteristic for SPTCL, with only localized pseudomembranous degeneration of fatty cells – a likely effect of chemotherapy. The course of the treatment was not marred by any major complications, no unexpected side-effects were noted. Only one major infection, *Candida* sepsis four months after initiation of chemotherapy had to be treated with systemic antifungal drugs outside the standard protocol. The planned treatment was nonetheless continued and completed according to schedule.

Twenty-four months after starting the treatment the boy is in remission and we discontinued the maintenance therapy (purinethol+methotrexate). Full 24 months after the diagnosis was established the protocol was completed and saw the child in full remission. Outpatient follow-up is in progress.

Discussion and Conclusion

Subcutaneous panniculitis-like T-cell lymphoma (SPTCL) is a distinctive skin lymphoma that is characterized by infiltration of subcutaneous tissue by neoplastic T-cells of cytotoxic phenotype mimicking panniculitis. Gonzales et al.¹ first described T-cell lymphoma involving the subcutaneous tissue in 1991. Willemze et al.³ analyzed the larger group of 83 cases. Their study show clear cut differences not only between SPTL with an $\alpha\beta$ T-cell phenotype (SPLT- $\alpha\beta$) and SPLT with a $\gamma\delta$ T-cell phenotype (SPLT- $\gamma\delta$), but also between SPLT- $\alpha\beta$ with and those without haemophagocytic syndrome (HPS). In contrast,

in the group of SPTCL- $\gamma\delta$ no difference in survival was found between patients with and patients without HPS.

Resulting from its rarity in childhood, there are no specific, widely accepted recommendations for treatment of subcutaneous panniculitis-like T-lymphoma inside that specific population group^{4,5}. Recently, Koh et al.⁶ presented the results of 16 cases of children treated from SPTCL clearly showing the variations in treatment modalities that ranged from monotherapy (prednisone or prednisone and cyclosporine) to multidrug chemotherapy followed by autologous peripheral blood stem cell transplantation.

In this report we present evidence for a good outcome after treatment with EURO-LB 02 protocol, a standard

in the therapy of other T-cell lymphomas of mature phenotype. Although our case does not present a definite guideline, it is indicative of the direction further treatment efforts should focus to. It is still uncertain whether the protocol should be supplemented with a prophylactic CNS irradiation treatment. Respecting the child's age at the time of diagnosis and taking into account that no clear benefit in survival rate resulting from radiation is established so far, we decided not to go through with it. Based on sporadic cases of children with SPTCL presented to date, we clearly argue that a definite treatment should be established and that the T-lymphoma therapy protocol, with or without additional radiation, could just be the one.

REFERENCES

1. GONZALEZ CI, MEDEIROS LJ, BRAZIEL RM, JAFFE ES, Am J Surg Pathol, 15 (1991) 17. — 2. WILLEMZE R, JAFFE ES, BURG G, CERRONI L, BERTI E, SWERDLOW SH, RALFKIAER E, CHIMENTI S, DIAZ-PEREZ JL, DUNCAN LM, GRANGE F, HARRIS NL, KEMPF W, KERL H, KURRER M, KNOBLER R, PIMPINELLI N, SANDER C, SANTUCCI M, STERRY W, VERMEER MH, WECHSLER J, WHITTAKER S, MEIJER CJ, Blood, 105 (2005) 3768. — 3. WILLEMZE R, JANSEN PM, CERRONI L, BERTI E, SANTUCCI M, ASSAF C, CANNINGA-VAN DIJK MR, CARLOTTI A, GEERTS ML, HAHTOLA S, HUMMEL M,

JESKANEN L, KEMPF W, MASSONE C, ORTIZ-ROMERO PL, PAULLI M, PETRELLA T, RANKI A, PERALTO JL, ROBSON A, SENFF NJ, VERMEER MH, WECHSLER J, WHITTAKER S, MEIJER CJ, Blood, 111 (2008) 838. — 4. SHANI-ADIR A, LUCKY AW, PRENDIVILLE J, MURPHY S, PASSO M, HUANG FS, PALLER AS, J Am Acad Dermatol, 50 (2004) 518. — 5. GO RS, WESTER SM, Cancer, 101 (2004) 1404. — 6. KOH MJ, SADARANGANI SP, CHAN YC, CHAN MY, TAN AM, TAN SH, TAY YK, NG SB, J Am Acad Dermatol, 61 (2009) 875.

Lj. Rajić

Department of Haematology and Oncology, Pediatric Clinic, Zagreb University Hospital Center and Zagreb University School of Medicine, Kišpatičeva 12, 10000 Zagreb, Croatia
e-mail: ljubica.rajic@yahoo.com

POTKOŽNI T-STANIČNI LIMFOM NALIK PANIKULITISU U 19-MJESEČNOG DJEČAKA: PRIKAZ SLUČAJA

SAŽETAK

Potkožni T-stanični limfom nalik panikulitisu (engl. subcutaneous panniculitis-like T-cell lymphoma, SPTCL) jest rijetki oblik T-staničnog limfoma fenotipa CD3+CD8+ kojeg karakteriziraju duboki kožni čvorići ili plakovi nalik panikulitisu, a koji nastaju kao rezultat infiltracije potkožnog masnog tkiva neoplastičnim limfocitima. U ovom radu prikazujemo slučaj 19-mjesečnog dječaka sa SPTCL koji je dijagnosticiran i uspješno liječen u našoj ustanovi. Bolest se isprva prezentirala visokom vrućicom i bolnim eritematoznim čvorićima ispod pupka. Kasnije su se infiltrati pojavili na licu, nogama, rukama i leđima. U postavljanju dijagnoze najodlučniji je bio patohistološki nalaz biopsije kože koji je pokazao infiltraciju atipičnih, malenih do srednje velikih limfatičnih stanica u dubljim slojevima dermisa i potkožnom tkivu oko adipocita. Na imunohistokemijskoj analizi neoplastični limfociti su izražavali biljege CD2, CD3, CD5, CD7, CD8, Tia-1, granzim-B i perforin, a bili su negativni na CD20, CD34, TDT i CD56. Nije nađena infiltracija krvnih žila i epidermisa. U djeteta je započeto liječenje protokolom specifičnim za T-stanične limfome (EURO-LB 02) što je uskoro dovelo do brzog povlačenja svih općih i lokalnih simptoma. Liječenje je završeno prema planu, a dijete je danas, 24 mjeseca od početka terapije u kompletnoj remisiji bolesti.