

Laryngeal inflammatory myofibroblastic tumor in a man: a case report

Brčić, Iva; Brčić, Luka; Hutinec, Zdenka; Prgomet, Drago; Seiwerth, Sven

Source / Izvornik: **Collegium Antropologicum, 2010, 34, 1127 - 1129**

Journal article, Published version

Rad u časopisu, Objavljena verzija rada (izdavačev PDF)

Permanent link / Trajna poveznica: <https://um.nsk.hr/um:nbn:hr:105:545276>

Rights / Prava: [In copyright](#)/[Zaštićeno autorskim pravom.](#)

Download date / Datum preuzimanja: **2024-11-23**



Repository / Repozitorij:

[Dr Med - University of Zagreb School of Medicine
Digital Repository](#)



Laryngeal Inflammatory Myofibroblastic Tumor in a Man: A Case Report

Iva Brčić¹, Luka Brčić², Zdenka Hutinec¹, Drago Prgomet³ and Sven Seiwert^{1,2}

¹ Clinical Department of Pathology and Cytology, Zagreb University Hospital Center, Zagreb, Croatia

² Institute of Pathology, School of Medicine, Zagreb University, Zagreb, Croatia

³ University Department of ENT, Head and Neck Surgery, Zagreb University Hospital Center, Zagreb, Croatia

ABSTRACT

Inflammatory myofibroblastic tumor (IMT) is a pseudosarcomatous lesion occurring in soft tissue and organs. It is known under a wide number of terms, such as inflammatory pseudotumor, plasma cell granuloma, pseudosarcomatous myofibroblastic proliferation. IMT is most commonly located in the lung, while laryngeal location is rarely described. Due to its' biology it can be misdiagnosed as a malignant tumor. We present a case of IMT of larynx, recognized in time and treated with laser ablation. Our case demonstrates the importance of timely IMT recognition in order to avoid overtreatment. This diagnosis should also alert clinicians to close follow-up of these patients.

Key words: inflammatory myofibroblastic tumor, larynx, immunohistochemistry

Introduction

Inflammatory myofibroblastic tumor (IMT) is a pseudosarcomatous lesion of uncertain origin occurring in soft tissue and organs. It is known under a wide number of terms, such as inflammatory pseudotumor, plasma cell granuloma, pseudosarcomatous myofibroblastic proliferation etc., partly reflecting its spectrum of appearance¹. It is most commonly located in the lung. In the head and neck region it usually occupies periorbital and orbital soft tissue. Location of IMT in larynx is very rare²⁻⁵, with 39 cases reported so far⁶. It is more common in male, with male to female ratio of 1.45:1, and the mean age at presentation is 43 years⁶. Because of infiltrative local growth, potential for recurrence, vascular invasion and distal metastasis it is regarded by some authors as a neoplastic process⁷.

The etiology and pathogenesis of this lesion still remains unresolved, although infection, trauma and irradiation are possible etiologic factors^{3,8}.

We present a case of a male patient with laryngeal IMT.

Case Report

A 67-year-old male presented with a several weeks history of persistent hoarseness. He had no history of

trauma or previous operation and was a non smoker. The physical examination was normal and no cervical lymphadenopathy was detected. Fiberoptic laryngoscopy demonstrated a tumorous mass in anterior glottic region. A biopsy was performed and revealed granulation tissue. After few weeks of antibiotic therapy further growth of the lesion was observed. On repeated biopsy pyogenic granuloma was diagnosed. Six weeks later, because of the progression of the lesion, new laryngoscopic examination showed a submucosal ulcerated nodular mass projecting from the anterior commissure into the subglottis, partially obstructing the lumen. Microlaryngoscopic biopsy followed by CO₂ laser ablation was performed and the specimens were sent for histological examination. The material consisted of several fragments up to 1.2 cm in the largest diameter. Histologically, they were mostly composed of spindle-shaped cells with long to plump nuclei of fibroblastic appearance displaying slight polymorphism (Figure 1a). Mitoses were present up to 4 per 10 high-power fields (HPF). Occasionally, especially toward the surface of the specimen, the nuclei displayed a more square, epitheloid shape. The surface epithelium was mostly eroded, covered by fibrin and cellular debris. Underneath was prominent granulation tissue with endothelial cells displaying pleomorphism (Figure 1b). Diffuse abundant inflammatory infiltrate was present throu-

ghout the material, composed mainly of granulocytes in the surface area and becoming more mononuclear toward the deeper regions. There was no necrosis. Immunohistochemically, most of the fibroblastic cells were vimentin and smooth muscle actin (SMA) positive (Figure 1c), while the epitheloid and pleomorphic cells also displayed CD31 (Figure 1d) and CD68 positivity. All tumor cells were negative for EMA, S-100, CK, desmin and ALK-1. Our final diagnosis was inflammatory myofibroblastic tumor, but because of the laser ablation procedure margins were not particularly analyzed. Additional treatment was not applied. Two years after the final diagnosis the patient is still alive, with recurrence of the tumor and progression to trachea.

Discussion

Because of its' biological behavior IMT can be regarded as a malignant tumor. The neoplastic theory has been supported by occasional recurrence and even metastatic potential of IMT (not reported for laryngeal localization). In addition, aneuploidy, clonality, chromosomal rearrangement (2p23), expression of ALK1 and p80 have also been demonstrated^{9–13}. According to the Volker et al., only 2 out of 20 laryngeal IMT demonstrated ALK-1 positivity, which does not have any real prognostic significance in IMT^{13–16}. The concept of IMT being an exuberant post inflammatory reaction is supported by its post-traumatic/postsurgery appearance as well as the successful application of anti-inflammatory drugs (both steroidal and nonsteroidal) in therapy^{17,18}.

The usual leading symptom is hoarseness; however dyspnea, stridor, dysphasia and dysphonia may also occur. Most commonly the lesions are flashy and firm in appearance, with polypoidal, pedunculated or nodular growth involving the vocal cords. Wenig et al. in their initial paper, where they presented the first series of 8 laryngeal IMT, mostly described them as being unencapsulated³. According to the most authors histological appearance is characterized by spindle or stellate cells distributed in a chronic inflammatory background and often displaying a storiform, nodular or fascicular proliferation pattern. The nuclei of these cells are rounded to oval and display a low-grade pleomorphism within the range of a *bona fide* benign lesion usually with a low mitotic rate (<2/10 HPF). The stroma can be myxoid, fibrillary or fibrous. The inflammatory infiltrate is mainly mononuclear, consisting of plasma cells with an admixture of lymphocytes, histiocytes and eosinophils. If the overlying mucosa is present, it can be ulcerated, inflamed or hyperplastic. The blood vessels can be scarce or abundant. Immunohistochemically, the stromal cells are usually positive for vimentin, SMA and muscle-specific actin^{2,3,17}. The spectrum of morphologic appearance, giving base to the spectrum of synonyms, ranges from lesions composed almost exclusively of plasma cells permeating fibroblastic/myofibroblastic stroma to inflammatory infiltrate devoid lesions composed only of myofibroblasts and named myofibroblastomas¹⁹. Others include in this spectrum the

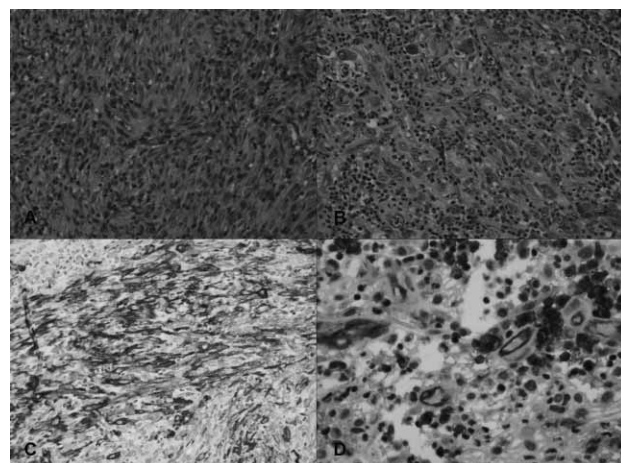


Fig. 1. Microscopical presentation of inflammatory myofibroblastic tumor. Tumor cells presented mainly as spindle-shaped cells with long to plump nuclei of fibroblastic appearance displaying slight polymorphism (a), and in granulation tissue pleomorphic endothelial cells were present (b). Immunohistochemically smooth muscle actin positivity was present in majority of the fibroblastic cells (c), while epitheloid and pleomorphic cells displayed CD31 positivity (d). (A and B, hemalaun and eosin stain, C and D immunohistochemistry).

inflammatory fibrosarcoma²⁰ and inflammatory leiomyosarcoma¹⁷. Differential diagnosis also includes inflammatory soft tissue neoplasms which supposedly follow a more aggressive course with recurrence and metastasis. In biopsy material including only superficial parts of an ulcerated lesion, the differentiation toward ulcerated spindle cell carcinoma can arise. One should also rule out lesions such as leiomyomas, solitary fibrous tumor, nodular fasciitis and peripheral nerve sheet tumor²¹. Because of all that, detailed histological and immunohistochemical analysis, preferably using vimentin, actin and CD68 is obligatory, but unfortunately not always helpful and without prognostic significance¹⁴.

The therapeutic approach of choice is a complete local excision, possibly followed by postoperative steroid application. Our patient had tumor recurrence after micro-laser ablative surgery, although there are reports of excellent outcomes after partial laser vaporization⁶. Radiation therapy can be successful in recurrent disease. Steroid or radiation therapy as sole treatment seems not to be quite effective¹⁷. Frequent follow-up with fiberoptic laryngoscopy and CT scans are recommended to search for recurrence.

Conclusion

The IMT of the larynx are usually of benign biological behaviour and their recognition and proper diagnosis is important in order to avoid unnecessary aggressive treatment. However, the most effective treatment is total excision. Even more, this diagnosis should alert clinicians to close follow-up of these patients.

REFERENCES

1. CORSI A, CIOFALO A, LEONARDI M, ZAMBETTI G, BOSMAN C, Am J Otolaryngol, 18 (1997) 121. — 2. COFFIN CM, WATTESON J, PRIEST JR, DEHNER LP, Am J Surg Pathol, 19 (1995) 859. — 3. WENIG BM, DEVANEY K, BISCEGLIA M, Cancer, 76 (1995) 2217. — 4. SUH SI, SEOL HY, LEE JH, LEE YH, KIM TK, LEE NJ, WOO JS, KIM IS, Head Neck, 28 (2006) 369. — 5. FERNÁNDEZ-ACEÑERO MJ, LARACH F, ORTEGA-FERNÁNDEZ C, Acta Otolaryngol, 129 (2009) 108. — 6. BIRON VL, WAGHRAY R, MEDLICOTT SA, BOSCH JD, J Otolaryngol Head Neck Surg, 37 (2008) 32. — 7. BARRETO DM, RODRIGUES LF, PATROCINIO LG, COELHO SR, PATROCINIO JA, Braz J Otorhinolaryngol, 74 (2008) 638. — 8. MUNOZ A, VILLAFRUELA M, Pediatr Radiol, 31 (2001) 459. — 9. GRIFFIN CA, HAWKINS AL, DVORAK C, HENKLE C, ELLINGHAM T, PERLMAN EJ, Cancer Res, 12 (1999) 2776. — 10. LAWRENCE B, PEREZ-ATAYDE A, HIBBARD MK, RUBIN BP, DAL CIN P, PINKUS JL, PINKUS GS, XIAO S, YI ES, FLETCHER CD, FLETCHER JA, Am J Pathol, 157 (2000) 377. — 11. GLEASON BC, HORNICK JL, J Clin Pathol, 61 (2008) 428. — 12. SU LD, ATAYDE-PEREZ S, SHELDON S, FLECHER JA, WEISS SW, Mod Pathol, 11 (1998) 364. — 13. COFFIN CM, PATEL A, PERKINS S, ELENITOBA-JOHNSON JK, PERLAN E, GRIFFIN CA, Mod Pathol, 14 (2001) 569. — 14. VÖLKER HU, SCHEICH M, HÖLLER S, STRÖBEL P, HAGEN R, MÜLLER-HERMELINK HK, ECK M, Diagn Pathol, 2 (2007) 1. — 15. CHUN YS, WANG L, NASCIMENTO AG, MOIR CR, RODEBERG DA, Pediatr Blood Cancer, 45 (2005) 796. — 16. VÖLKER HU, SCHEICH M, ZETTL A, HAGEN R, MÜLLER-HERMELINK HK, GATTENLÖHNER S, Head Neck, Epub (2009). — 17. IDREES MT, HUAN Y, WOO P, WANG BY, Ann Diagn Pathol, 11 (2007) 433. — 18. SU W, KO A, O'CONNELL T, APPLEBAUM H, J Pediatr Surg, 35 (2000) 1635. — 19. MACGREGOR AR, BATSAKIS JG, EL-NAGGAR AK, Head Neck, 25 (2003) 606. — 20. MEIS-KINDBLÖM JM, KJELLSTROM LG, Semin Diagn Pathol, 15 (1998) 133. — 21. GUILEMANY JM, ALOS L, ALOBID I, BERNAL-SPREKELSEN M, CARDESA A, Acta Otolaryngol, 125 (2005) 215.

S. Seiwert

*Institute of Pathology, School of Medicine, Zagreb University, Šalata 10, 10000 Zagreb, Croatia
e-mail: seiwert@mef.hr*

INFLAMATORNI MIOFIBROBLASTIČNI TUMOR LARINKSA: PRIKAZ SLUČAJA

SAŽETAK

Inflamatorni miofibroblastični tumor (IMT) je pseudosarkomatozna lezija mekih tkiva i solidnih organa. Poznat je pod brojnim nazivima kao što su inflamatorni pseudotumor, plazmastanični granulom ili pseudosarkomatozna miofibroblastična proliferacija. IMT se najčešće nalazi u plućima, a izuzetno je rijedak u larinksu. Zbog svog biološkog ponašanja može se pogrešno dijagnosticirati kao maligni tumor. Predstavljamo slučaj IMT larinksa, koji je na vrijeme prepoznat i liječen laserskom ablacijom. Ovaj slučaj pokazuje važnost prepoznavanja IMT kako bi se izbjeglo nepotrebno, agresivno liječenje, ali i nužnost praćenja ovakvih pacijenata.