

The application of ultrasound in neuroendoscopic procedures: first results with the new tool »NECUP-2«

Jednačak, Hrvoje; Paladino, Josip; Miklić, Pavle; Mrak, Goran; Vukić, Miroslav; Štimac, Tihomir; Klarica, Marijan

Source / Izvornik: **Collegium Antropologicum, 2011, 35, 45 - 49**

Journal article, Published version

Rad u časopisu, Objavljena verzija rada (izdavačev PDF)

Permanent link / Trajna poveznica: <https://um.nsk.hr/um:nbn:hr:105:617896>

Rights / Prava: [In copyright](#)/[Zaštićeno autorskim pravom.](#)

Download date / Datum preuzimanja: **2024-07-14**



Repository / Repozitorij:

[Dr Med - University of Zagreb School of Medicine Digital Repository](#)



The Application of Ultrasound in Neuroendoscopic Procedures: First Results with the New Tool »NECUP-2«

Hrvoje Jednačak¹, Josip Paladino¹, Pavle Miklič¹, Goran Mrak¹, Miroslav Vukić¹, Tihomir Štimac² and Marijan Klarica³

¹ University of Zagreb, Zagreb University Hospital Centre, School of Medicine, Department of Neurosurgery, Zagreb, Croatia

² Acoustics Department, Marine Research & Special Technologies, Brodarski Institute, Zagreb, Croatia

³ University of Zagreb, Croatian Institute for Brain Research and Center for Clinical Research in Neuroscience, Zagreb, Croatia

ABSTRACT

In this paper, our experience with originally constructed Neurosurgical Endoscopic Contact Ultrasound Probe »NECUP-2« in neuroendoscopy is reported. Between June 1997 and June 2007, 132 neuroendoscopic procedures have been performed: 102 endoscopic third ventriculostomies (ETV), 15 arachnoid cysts and 5 intraventricular tumours operations. The »NECUP-2« was applied effectively in all cases in which blunt perforation was not possible: 38/102 ETV, 10/10 septostomies, 15/15 arachnoid cysts. In five cases of intraventricular tumours, neuroendoscopic procedure was combined with open microsurgery for tumour removal with preservation of vascular structures. There were no »NECUP-2« related complications. Of postoperative complications, we had liquorrhea (9 patients), and symptoms of meningitis (6 patients). In the follow-up period (6 months to 6 years), we had a patency rate of 80% (50/63 patients). All patients improved in clinical status. According to the first results, it seems that ultrasonic contact probe NECUP-2 presents a new device in neurosurgical armamentarium that can be used in various fields of neurosurgery. With minimal and controlled lesion that is produced at the tip of the probe, it can be used in highly demanding operations such as third ventriculostomy and tumour resection.

Key words: endoscopic neurosurgery, high energy ultrasound, third ventriculostomy

Introduction

There are two major applications of ultrasound in medicine: diagnostic and therapeutic. Diagnostic use of ultrasound is spread throughout medicine in a way that we cannot imagine medical practice without the use of ultrasound as a screening test for abdominal, obstetrician or cardiologic segment of medicine. In this work, the authors are dealing with ultrasonic waves that are used for therapeutical purposes, especially with ultrasound that is used in the surgical procedures. First report of using the high energy ultrasound for phacoemulsification in cataract surgery appeared in 1967¹. With further research and development in theoretical and practical knowledge on acoustics of high energy ultrasonic wave, it found its use in other fields of medicine. Since 1980's, high energy ultrasonic waves are used in the neurosurgical practice^{2,3}. High energy ultrasound is used to remove brain

tumours with mechanical degradation of soft tissue by means of primarily cavitation, and less of thermal effect. Cavitation means relatively pointed mechanical emulsification of soft tissue. This characteristic of ultrasound is greatly used in ophthalmology, dentistry and general surgery. Adding the aspiration to the ultrasonic resonator produced a new and useful instrument for dealing especially with soft tissue tumours and other lesions that had to be removed carefully regarding the preservation of the surrounding tissue.

With the development of technology and spread of »minimally invasive neurosurgical« philosophy, some new demands were presented concerning the use of the high energy ultrasound. Wider use of endoscopes, and smaller craniotomies with minimal lesion to the brain proposed

further development of ultrasonic surgical equipment. Surgeons needed an instrument that can perform punctiform, well-circumscribed and controlled lesion with minimal or, even better, no dispersion and lesion to normal tissue. Therefore, in 1995, scientists and clinicians from School of Electrical Engineering, Department of Neurosurgery School of Medicine, University of Zagreb, and Brodarski Institute for Marine Research and Special Technologies began to work on a new device that uses high energy ultrasound for neurosurgical purposes. On the basis of the theoretical model, the NECUP (Neurosurgical Endoscopic Contact Ultrasonic Probe) has been realized as a rod-type resonant vibrating system, consisting of a half-wave length transducer of piezoceramic material, and a resonant wave guide in the form of a specially shaped mechanical concentrator with titanium wire⁴. The aim was to produce high energy ultrasonic point source for minimally invasive neurosurgery, especially for endoscopic use. Emphasis is on the contact point source of energy. That means we can perform the degradation of tissue by touching it with the tip of the probe, with little or no surrounding lesion. This was performed by means of the conducted theoretical analysis (calculation and modeling) of optimized ultrasonic transducers, high power ultrasonic source for minimally invasive neurosurgery that would be used especially for endoscopic third ventriculostomy (ETV) in patients suffering from a noncommunicating hydrocephalus.

The first prototype called NECUP-1 was experimentally and clinically tested, and results were reported⁴⁻⁸. Since the introduction of NECUP-1 in 1999, there have been new ideas for better and easy-to-use performance of the device. Under the sponsorship of the Center for Clinical Research in Neuroscience, a technologic project named »The neurosurgical endoscopic contact ultrasonic probe« has been developed by the Department of Neurosurgery, School of Medicine, School of Electrical Engineering and Computing, University of Zagreb and Brodarski Institute. Within this project, a new prototype called NECUP-2 has been developed for use in scientific and clinical research. The aim of this work is to present the first results of the clinical application of NECUP-2 in minimally invasive neurosurgery.

Methods

Technical aspects

In order to fulfill primary objective of the construction of the NECUP-2, which is simplification and improvement of the surgical procedures in the treatment of hydrocephalus and certain types of cystic and tumor diseases in hardly accessible and functionally important regions of the brain tissue, the optimization of the probe was conducted. The theoretical model used for the optimization covers three major parts of the probe: piezoelectric transducer, mechanical concentrator and endoscopic tool. The main design requests were:

- reducing ultrasonic probe dimensions (length, diameter) and mass;

- ensuring surgeon's complete field of view under operational microscope or endoscope during the procedure;
- shaping the probe to ensure reaching shallow and deep seated lesions;
- ensuring sufficient mechanical energy for fragmentation of firm cystic formations;
- designing the probe ergonomically;
- possibility of NECUP applications in the different surgical procedures.

The intrinsic mechanical resonant frequency of the piezoelectric transducer in our case was approximately 24800 Hz. The emitted acoustic power, sound pressure distribution in the free field (vertical and horizontal plane) and the efficiency coefficient of the ultrasonic probe have been determined experimentally in an anechoic hydroacoustical tank⁶. The experimental results in laboratory animals were encouraging (long-lasting punctiform tissue lesion with clear margins was obtained) and led us to clinical application of the NECUP in the endoscopic third ventriculostomy procedures.

The model NECUP-2 consists of: ultrasonic generator, ultrasonic probe, foot switch, power cord and various tips in different shapes, thickness and length. Line voltage 220V/50 Hz is being transformed in the ultrasonic generator into the electrical source of power of 100 W and frequency of 24000 – 25000 Hz. Ultrasonic generator is charging piezoelectrical converter that transforms electrical energy into mechanical. Mechanical energy of complex piezoelectrical converter (Ø 15 mm) is concentrated with mechanical concentrator of energy-sonotrode whose diameter is Ø 5 mm (approximated coefficient of transformation is 88). At the top of the titanium wire, strong longitudinal vibrations are obtained (25 000 beats in second; so-called »hammer effect«) which make ultrasonic cavitation. With this effect fragmentation of tissue, that we want to eliminate, is obtained.

The newly designed NECUP-2 is 1.6 mm in diameter and easily passes through the 2 mm ventriculoscope working channel (Figure 1). We used Aesculap ventriculoscope. The principle of endoscopic ultrasonic surgery with its performance of direct cutting, cavitation, fragmentation and thermal damage enables simple removal of the desired tissue performed in the visual field of a ventriculoscope video camera.




Fig. 1. Sonotrode entering the ventriculoscope and sonotrode tip within the ventriculoscope's working channel.

Clinical procedure

NECUP-2 is used in endoscopic neurosurgery to perform small, punctiform opening at the floor of third ventricle, endoscopic third ventriculostomy (ETV)⁸. After preoperative preparation, patients are introduced into general anesthesia. Through the small skin incision and small craniotomy on the right frontal side, dural incision is performed. Ventriculoscope is introduced into the right lateral ventricle, and through foramen of Monroe it passes into the third ventricle. After the inspection of the ventricle, mamillary bodies are identified, and slightly in front of them is premamillary membrane. Through the working channel of the ventriculoscope, the tip of the ultrasonic contact probe is introduced, and gently applied to premamillary membrane. With a small ultrasonic energy, the membrane is opened and the opening is widened by a balloon catheter. Contact probe is removed, and the endoscope is introduced through the opening to inspect interpeduncular cistern.

In cases of unilateral hydrocephalus due to any kind of obliteration of foramen of Monroe (such as atresia or reduction of diameter of foramen), we perform septostomy. After entering the lateral ventricle on the side of the larger ventricle, either from frontal side or from trigonum of the ventricle, we inspect the region of foramen of Monroe to verify the diagnosis. Then we turn the ventriculoscope to visualize the septum pellucidum. With ultrasonic energy, we perform several openings in the septum which we join into one large opening using the balloon catheter.

In patients with arachnoidal cysts, we recognize two different groups of patients. First group consists of patients with extracerebral, usually temporal or convexity arachnoidal cysts, and the second group consists of patients with intraventricular or suprasellar arachnoidal cysts. According to this selection, the neuroendoscopic approach varies, but the main goal is to visualize the arachnoidal wall of the cyst and to make the opening in the cyst wall, connecting the cyst to other CSF pathways, either the basal subarachnoidal cisterns or ventricles.

Results

Since the introduction of the probe, 63 patients (with approval of the Ethical Committee at our Hospital and signed consent by the patients) have been operated on using the »NECUP-2«. A total of 38 patients were operated on for the problems of noncommunicating hydrocephalus (Figure 2), 10 patients were operated on for unilateral hypertensive hydrocephalus and 15 patients were operated on for arachnoidal cysts (Figure 3). All of the patients presented with the symptoms of raised intracranial pressure, which are intense headache, nausea, vomiting, somnolence and rarely epilepsy. There have been 29 males and 34 females, ranging from 2 months to 76 years of age, mean age of 37 years.

There were no intraoperative complications with this technique. Of postoperative complications, we had liquo-

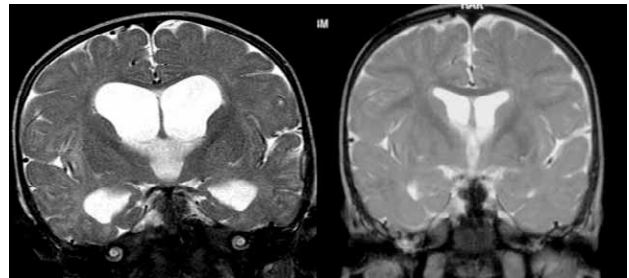


Fig. 2. Noncommunicating hydrocephalus in a 8-months old girl (left preoperative MRI; right postoperative MRI).

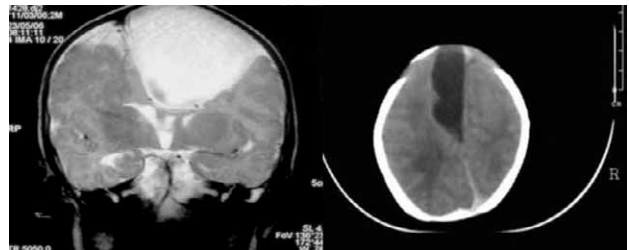


Fig. 3. Parasagittal cyst in a 2-month old boy (left preoperative MRI; right postoperative CT scan).

rrhea in 9 (14.3%) patients. Four of them needed surgical dural repair. In other 5 patients, liquorrhea ceased after the implementation of external lumbar drainage. Also, there were 6 (9.5 %) patients that developed symptoms of meningitis and were treated with antibiotics. In follow-up ranging from 6 months – 6 years we had a patency rate of 80% (50/63 patients). Eight patients in the group of noncommunicating hydrocephalus with obliterated stoma needed classical ventriculoperitoneostomy because of the recurrent hydrocephalus. Patients in the group of unilateral hydrocephalus who were operated on with septostomy showed clinical improvement in the follow-up. All of them were symptoms free. This is because we could perform a wide opening in the septum pellucidum, thus bypassing the obliterated foramen of Monroe. The size of ventricles was decreased in 31 patients as an objective sign of a successful surgery. In patients with arachnoidal cysts (15/63), we observed 4 cases with the obliteration of stoma during the follow-up, and the second operation using the microscope was performed. Those were patients with the temporally located cysts.

All patients improved in clinical status at the end of the follow-up period, without preoperative symptoms, except for seven patients (7/63, 11%) that remained with mild transient headache and were treated conservatively with analgetics.

Discussion

Main requirements during the construction of the contact ultrasonic probe were derived from specific application in endoscopic third ventriculostomy, and can be described as following: the ultrasonic probe has to deliver

sufficient amount of acoustic power into the operating area, ultrasonic probe has to be designed to transform electric energy into the acoustic one, and transmit it over the saline in the targeted tissue, and it has to concentrate mechanical energy in the narrow zone near the probe tip. The construction is based on the transformation of electrical energy by composite piezoelectric ultrasonic transducer into longitudinal vibrations of titanium wire of 1.6 mm in diameter and 330 mm in length^{5,9}. This ultrasonic surgical device is essentially a rod-type resonant vibrating system, consisting of a half-wavelength piezoelectric transducer and a resonant waveguide in the form of a specially shaped velocity transformer (sonotrode), driven by an electronic generator. The design of the titanium sonotrode increases maximum vibration amplitude up to an effective amplitude of 360 μm at the distal end. When sound pressure waves come into contact with the tissue, the rapid motion of the tip creates alternating densities in the fluid, in and around the tissue. If the tissue has high water content, the resulting pressure pulses cause cavitation at high negative sound pressure, and implosion of these cavitations at high pressure¹⁰. The tip also causes a rapid vibration of the tissue which it comes in contact with, resulting in tearing the tissue away from the surrounding structures, called »hammer effect«¹¹.

Third ventriculostomy is performed usually by opening of the floor of the third ventricle between the mammillary bodies to the subarachnoidal space of interpeduncular cistern¹². It has been done through the endoscope, and the opening was made either by blunt perforation, or by monopolar electrocoagulation. Underneath the floor of the third ventricle lies basilar artery, and there were reports of rupturing the artery during the procedure, ending lethally for the patient, in the literature¹³.

Therefore, our concern was to perform a proper opening at the floor of the third ventricle and to reduce the risk of lesion to the basilar artery. Using »NECUP-2«, we were assured that the perforation of the floor of the third ventricle can be done in a safe manner regarding the range of the ultrasonic power applied at the tip of the probe. Therefore, at each step of the perforation of the floor with the »NECUP-2«, we were able to observe changes in the thickness of the premamillary membrane. In especially thick and nontransparent premamillary membrane, by gradation of the ultrasonic power we performed a safe and correct perforation with preservation of content of interpeduncular subarachnoid cistern.

We did not have any complications during the procedure. During the follow-up period, the real incidence of complications related to ETV is difficult to establish due to the fact that there is no clear definition of what should be considered a complication in the literature. In our series, we have observed 6 liquorrheas and 3 infections, which is comparable with the number of different com-

plications (e.g. 1. vascular complications – subdural hematoma; intraventricular hemorrhage; intracerebral hematoma; arterial or venous bleeding; 2. infections; 3. cranial nerve deficit, 4. neurological deficit – CSF leakage; hemianopia; hemiparesis; memory loss; etc.) that occurred in large series published in literature^{14–16}. Obtained patency rate (79%, 30/38 patients) at the end of follow-up period in our series of ETV (up to 6 years) is similar to those in follow-up period (up to 5 years) shown in recent reviews^{14–17}.

In the other two groups of patients with unilateral hydrocephalus and arachnoidal cysts, our data indicates good results in controlling the unilateral hydrocephalus with septostomies. Also, with gradation of ultrasonic power applied at the tip of the probe, we were able to preserve small capillaries in the septum pellucidum. They were concentrated in the trabecular remnant of the septum while large fenestration of avascular portion of septum pellucidum is done. With preservation of small vessels, we were able to shorten operative time and to maintain high patency rate at the follow-up. Also, good results are observed in patients with arachnoidal cysts that were operated on using cystoventriculostomy. Patients with temporally located arachnoidal cysts showed less favorable results because of the more frequent obliteration of the stoma. Sometimes this is due to the anatomical relations of the cyst wall and the nearby basal cistern, so the perforation could not be larger.

Conclusion

Endoscopic ultrasonic contact probe is a new instrument in neurosurgical armamentarium. Construction of the endoscopic ultrasonic contact probe NECUP-2 showed excellent collaboration between scientists from various fields in an effort to reduce operative risk for demanding patients. With minimal and controlled lesion that is produced at the tip of the probe, it can be used in a highly demanding operation such as third ventriculostomy. According to our first results obtained with »NECUP-2«, it seems that the application of such a device can be widened to other neurosurgical procedures in which minimal and controlled effect is needed such as tumour or lumbar disc surgery. With the possibility of various diameters of sonotrode tips, it can be used not only in neurosurgery, but in other surgical specialities that treat soft tissue diseases.

Acknowledgements

This work was sponsored by the Croatian Ministry of Science and Technology (projects: 108-1080231-0023; 108-1080231-0324; 108-1080231-0022; 108-1080231-0524; 108-1080231-0024)

REFERENCES

1. KELMAN C, *Am J Ophthalmol*, 40 (1967) 23. — 2. EPSTEIN F, *Clin Neurosurg*, 31 (1983) 497. — 3. BROCK M, INGWERSEN I, ROGGENDORF W, *Neurosurg Rev*, 7 (1984) 173. — 4. ŠTIMAC A, Assessment of the high-power ultrasound point source for the minimally invasive surgery, In: Proceedings (World Congress on Ultrasonics, Paris 2003). — 5. ŠTIMAC A, Assessment of a high-power ultrasound point source for minimally invasive surgery, PhD thesis. In Croat. (University of Zagreb, Zagreb, 2003). — 6. ŠTIMAC D, The effect of ultrasonic aspirator on neural tissue, PhD thesis. In Croat. (University of Zagreb, Zagreb, 1999). — 7. PALADINO J, ROTIM K, ŠTIMAC D, PIRKER N, ŠTIMAC A, *Min Inv Neurosurg*, 43 (2000) 72. — 8. PALADINO J, ROTIM K, ŠTIMAC D, PIRKER N, ŠTIMAC A, *Min Inv Neurosurg*, 43 (2000) 132. — 9. ŠTIMAC A, ŠTIMAC T, Optimisation of the endoscopic surgical ultrasonic probe. In: Book of abstracts (The First Croatian Congress of Neuroscience, Zagreb, 2003.). — 10. ŠTIMAC A, PALADINO J, KLARICA M, ŠTIMAC T, The neurosurgical endoscopic contact ultrasonic probe: technological aspects. In: Book of abstracts (The First Croatian Congress of Neuroscience, Zagreb, 2003). — 11. IVANČEVIĆ B, PATOŠIĆ A, JAMBROŠIĆ K, Development of neurosurgical contact ultrasonic probe. In: Book of abstracts (The First Croatian Congress of Neuroscience, Zagreb, 2003). — 12. BROCKMEYER D, *Neurosurg Clin N Am*, 15 (2004) 51. — 13. ABTIN K, THOMPSON BG, WALKER ML, *Pediatr Neurosurg*, 28 (1998) 35. — 14. ABOT R, *Neurosurg Clin N Am*, 15 (2004) 9. — 15. HELLWIG D, GROTENHUIS JA, TIRAKOTAI W, RIEGEL T, SCHULTE DM, BAUER BL, BERTALANFFY H, *Neurosurg Rev*, 28 (2005) 1. — 16. BROCKMEYER D, ABTIN K, CAREY L, WALKER ML, *Pediatr Neurosurg*, 28 (1998), 236. — 17. BEEMS T, GROTENHUIS JA, *Childs Nerv Syst*, 20 (2004), 868. — 18. FENG H, HUANG G, LIAO X, FU K, TAN H, PU H, CHENG Y, LIU W, ZHAO D, *J Neurosurg*, 100 (2004), 626.

H. Jednačak

University of Zagreb, Zagreb University Hospital Centre, School of Medicine, Department of Neurosurgery, Kišpatićeva 12, 10000 Zagreb

e-mail: hrvoje.jednacak@zg.t-portal.hr

UPOTREBA ULTRAZVUKA U NEUROENDOSKOPSKIM PROCEDURAMA: PRVI REZULTATI S NOVIM UREĐAJEM »NECUP-2«

SAŽETAK

U ovom radu prikazano je naše iskustvo sa originalno konstruiranom »NECUP-2« (Neurosurgical Endoscopic Contact Ultrasound Probe) sondom u neuroendoskopiji. Između lipnja 1997 i lipnja 2007, učinili smo 132 neuroendoskopske procedure: 102 ETV, 10 septostomija, 15 arahnoidalnih cisti i 5 intraventrikularnih tumora. »NECUP-2« je efikasno korišten u svim slučajevima u kojima se nije mogla učiniti tupa perforacija: 38/102 ETV, 10/10 septostomija, 15/15 arahnoidalnih cista. U pet slučajeva intraventrikularnih tumora neuroendoskopija se kombinirala sa otvorenom mikrokirurgijom uz očuvanje vaskularnih struktura. Nismo zabilježili komplikacije vezane uz upotrebu »NECUP-2«. Od poslijeoperacijskih komplikacija zabilježene su dvije likvoreje i u šest bolesnika simptomi meningitisa. U praćenju bolesnika (od 6 mjeseci do 6 godina) zabilježena otvorenost stome od 80% (50/63 bolesnika). Svi bolesnici su imali poboljšan poslijeoperacijski klinički status. Prema prvim rezultatima čini se kako ultrazvučna kontaktna proba »NECUP-2« predstavlja novi uređaj u neurokirurškom armamentarijumu koji se može koristiti u raznim poljima neurokirurgije. Minimalnom i kontroliranom lezijom koja se proizvodi na vrhu probe može se koristiti u visoko zahtjevnim operacijama kao što je treća ventrikulostomija ili resekcija tumora.