

Tremor, seizures and psychosis as presenting symptoms in a patient with chronic Lyme neuroborreliosis (Lnb)

Markeljević, Jasenka; Šarac, Helena; Radoš, Marko

Source / Izvornik: **Collegium Antropologicum, 2011, 35, 313 - 318**

Journal article, Accepted version

Rad u časopisu, Završna verzija rukopisa prihvaćena za objavljivanje (postprint)

Permanent link / Trajna poveznica: <https://urn.nsk.hr/urn:nbn:hr:105:329392>

Rights / Prava: [In copyright](#)/[Zaštićeno autorskim pravom.](#)

Download date / Datum preuzimanja: **2024-08-27**



Repository / Repozitorij:

[Dr Med - University of Zagreb School of Medicine Digital Repository](#)



Tremor, Seizures and Psychosis as Presenting Symptoms in a Patient with Chronic Lyme Neuroborreliosis (Lnb)

Jasenka Markeljević¹, Helena Šarac² and Marko Radoš³

¹ University of Zagreb, School of Medicine, Zagreb University Hospital Centre, Department of Internal Medicine, Zagreb, Croatia

² University of Zagreb, School of Medicine, Zagreb University Hospital Centre, Department of Neurology and Croatian Institute for Brain Research, »Neuron« Diagnostic Centre, Zagreb, Croatia

³ University of Zagreb, Croatian Institute for Brain Research, Department for Radiology, Zagreb, Croatia

ABSTRACT

Lyme borreliosis is a multisystem disorder caused by Borrelia burgdorferi (Bb). Neurological symptoms such as lymphocytic meningoradiculoneuritis (Bannwart's syndrome), cranial neuritis (II,III,IV,V,VI), encephalitis, transverse myelitis are found in about 10% of cases during the second phase of the disease. In the chronic stage, many months or years after the initial infection, other neurologic complications may occur, such as encephalomyelitis, epileptic crises, cognitive impairment, peripheral neuropathy and psychiatric disturbances such as depression, anxiety, panick attacks, catatonia, psychosis etc. Some patient continue to experience symptoms of fatigue, insomnia or psychiatric disorder in the post borrelia syndrome. We describe here a patient with a triad of unusual symptoms in chronic LNB including tremor, seizures and psychosis. Standardized medical interview, neurologic examination, neuroimaging, serum and CSF serology as well as EEG and EMNG evaluation were performed. The patient was treated with intravenous ceftriaxone and doxycycline and responded with rapid clinical and functional improvement. Nevertheless, he suffered from multiple systemic and neurologic sequelae that influenced his daily activities in post treatment period. Emphasis is placed on the atypical onset and evolution, the difficulties encountered in formulating diagnosis, early treatment and the uncertainties concerning the sequelae after treatment. In patients with non-specific long lasting symptoms in the absence of overt clinical signs suggesting CNS involvement, routine treatment with i.v. ceftriaxone is not to be encouraged.

Key words: tremor, seizurs, psychosis, chronic Lyme neuroborreliosis

Introduction

Lyme borreliosis (LB) is a tick-borne-transmitted multisystem inflammatory disease caused by the spirochete *Borrelia burgdorferi* (Bb)¹. Transmission of Bb requires at least 24–48 hours of tick attachment². Most patient do not recall the tick bite³. LB occurs in stages, with a spectrum of clinical signs. Within a few days of the tick bite, following intradermal inoculation, expanding erythema ≥ 5 cm in diameter, known as *Erythema migrans*, may be evident⁴ (stage 1.). After incubation from 3–32 days Bb invades the blood stream to cause a spirochetemia causing flulike symptoms of fever, headache, malaise, and myalgias⁴. A few weeks to few months after infection there is often resolution of earlier symptoms and evolution of early Lyme disease corresponding with rheu-

matic, neurologic and cardiac symptoms (stage 2.). Arthritis, myocarditis, migrating musculoskeletal pain, in limited joints, bursae, tendons, muscle, or bone is a common feature of early Lyme disease⁵. Subacute onset of a chronic basilar lymphocytic meningitis with or without encephalopathy, cranial neuritis and radiculopathy, so called Bannwart's syndrome in the European variant^{6–8} is often seen in this stage of neuroborreliosis. The neurological complications include: meningitis, facial palsy, usually bilateral, oculomotor palsy, optic neuritis, trigeminal neuralgia, encephalitis, transverse myelitis, polyradiculopathy with severe pain, sensory and motor loss, mononeuritis multiplex, myositis⁴. Many months, up to a year or more, after the initial infection, other late-onset

neurologic complications may occur (stage 3): encephalopathy can present as severe encephalomyelitis complicated by seizures⁹ or can be more mild, with mild memory and mood disturbances, word letter reversals, and spatial disorientation¹⁰. Major depression, anxiety, panic attacks and catatonia have been reported^{11–14}. Peripheral neuropathy, axonal in nature, both sensory and motor can be presented as a radiculopathy, plexopathy, distal neuropathy or mononeuritis multiplex^{15,16}. Some patients treated for lyme disease continue to experience some non-specific symptoms of fatigue, insomnia or psychiatric disorder, so called post borrelia syndrome (stage 4.).

We present one patient with late and chronic Lyme-neuroborreliosis, characterized by tremor, seizure and psychiatric disturbances. Emphasis is placed on the atypical onset, presentation and evolution, the difficulties encountered in determining diagnosis and uncertainties concerning the therapy.

Case Report

A 45-year old hunter developed tremor, occipital headache, vertigo, transient clenching of his teeth accompanied with low grade temperature up to 37.2°C in December, 2004. Symptoms gradually worsened in the following months when he exhibited myoclonic jerks of the right arm extending to the neck and shoulder. He approached the psychiatric clinic several times because of cognitive dysfunctions and behavioral symptoms including dissociative episodes accompanied with aggressive behavior and frank psychosis. Ten months later, in October 2005, when he was admitted to the department of neurology, he was psychotic and developed severe tremor, right side

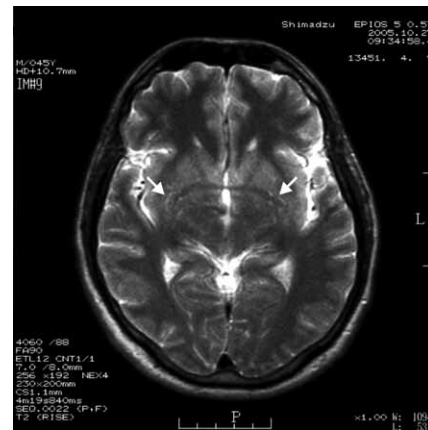


Fig. 1. Initial coronal MRI of the brain in T2 weighted images shows several punctiform hyperintense subcortical lesions in the frontal and parietal lobes (Oct, 2005).

myoclonic jerks and startle response. He appeared poorly oriented and his thoughts were incoherent. At the same time, a mitral valve insufficiency was detected in the absence of pulmonary hypertension. Initial MRI T2 weighted images demonstrated several punctiform hyperintense subcortical lesions in the frontal and parietal lobes (Figure 1). Initial EEG revealed low-voltage background activity and generalized paroxysms of slow waves 4–5 Hz lasting 1–3 seconds without asymmetry, that appeared more frequently during hyperventilation and fotostimulation, without asymmetry. Laboratory analysis showed negative *Treponema pallidum* hemagglutination assay (TPHA), negative brucellosis and tularemia serology tests. The diagnosis of Lyme borreliosis was considered and was later confirmed by the presence of a high titre of serum anti-

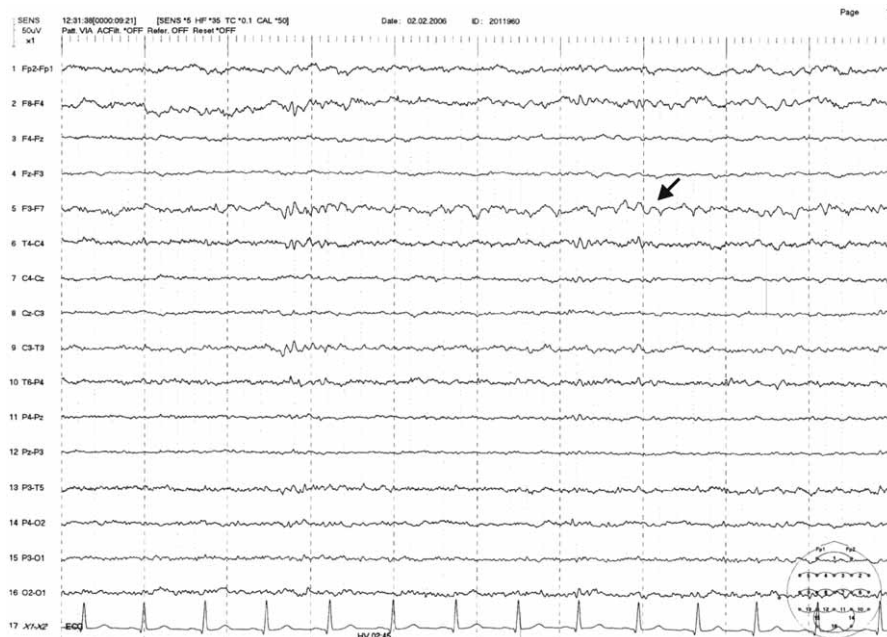


Fig. 2. Control EEG demonstrated low voltage background activity and slow waves over; frontal, temporal and central regions, with asymmetry over left anterior region (Feb, 2006).

bodies (IgG against *Borrelia burgdorferi* in a titre of 1:2560); ELISA: IgG 226 RU/mL, and IgM was negative. Cerebrospinal fluid (CSF) analysis showed total protein 1.4 g/L, high pleocytosis (960/3, mononuclear lymphocyte 100%, erythrocyte 30/3, proteins 1.4 g/L), and intratecal synthesis of IgG specific to *Borrelia burgdorferi*. The diagnosis of Lyme neuroborreliosis was established in the absence of the patient's recall of the tick bite or any skin lesion. The patient was treated with intravenous ceftriaxone 2g/per day during 35 days following by oral doxycyclin 100 mg twice a day and responded with rapid clinical and functional improvement, but not in complete recovery. The Jarish Herxheimer reaction was seen when antibiotics were having a therapeutic effect. There was a transient worsening in the psychiatric and cognitive symptoms which required close monitoring. As the psychiatric symptoms became increasingly difficult to treat, antibiotic treatment was combined with psychiatric treatment. Combined treatment resulted in improvement of neuropsychiatric symptoms. Control EEG (Figure 2) demonstrated low voltage background activity and with interposed slow waves 5–6 hz over frontal, temporal and central regions, with discrete assymetry over the left anterior region. Neuropsychological testing, which was conducted later, revealed conversive symptomatology. He was free from fever for 2 weeks, when he became subfebrile again 37.0°C. Since this antibiotic and psychiatric treatment did not lead to a total remission of neuropsychiatric symptoms, he was admitted to the infectious disease department again, in May, 2006. Neuropsychological testing showed persistent conversive symptomatology. He complained of visual disturbances, paresthesias in the fingers of both arms and legs, increased perspiration, anxiety and insomnia. At this time, he was free of seizures, myotonia and psychosis. The neurological examination revealed gentle tremor and mild behavioral disturbances. CSF analysis revealed normalisation of the CSF pleocytosis and low residual pleocytosis was noticed (25/3). Serum testing showed *Borrelia burgdor-*

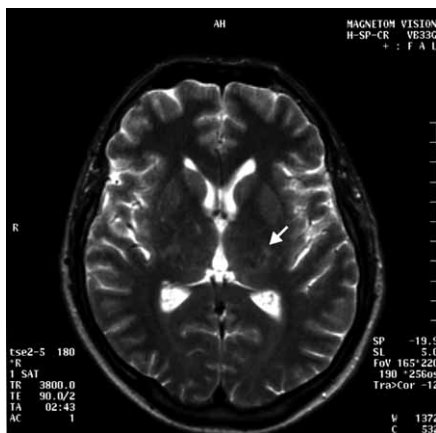


Fig. 3. Control MRI of the brain in T2 sequences was unchanged in comparison to the initial MRI and showed punctiform hyperintense subcortical lesions in the frontal and parietal lobes (Sep, 2006).

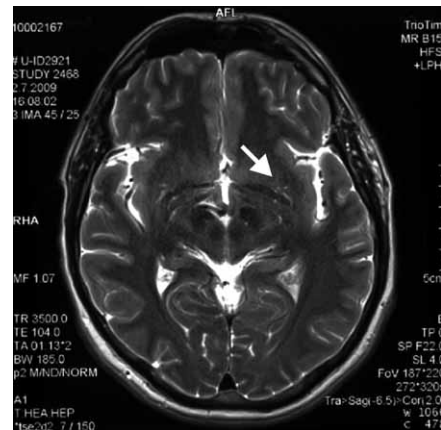


Fig. 4. Control MRI of the brain in T2 weighted images showed prominently widened perivascular spaces; in the deep white matter on the bounds between medium and inferior frontal gyrus, perivascular white matter along trigonum of the right lateral ventricle, in the thalamus and superior frontal gyrus (July, 2009).

feri IgG 22.2 and IgM 3.0 g/L. He received ceftriaxon (2 weeks) followed by doxycycline (2 weeks) again. After this treatment, he was free of tremors, but he still suffered from prolonged low-grade temperature 37.0°C, visual disturbances, flashes, and painful distal paresthesias. Control MRI of the brain was unchanged in comparison to the initial one and showed numerous punctiform hyperintense subcortical lesions in the frontal and parietal lobes (Figure 3). When he approached the department of infectious disease one year later, in June, 2007 he referred to a new tick bite seven months ago without associated skin lesion. At this time, he had almost recovered from tremor and partial motor seizures, but he still suffered from visual disturbances, painful paresthesia in arms and legs, anxiety, depression and concentration disturbances, headache and low-grade fever. CSF analysis revealed 14/3 cells (mononuclears 100%), cytological finding (lymphocyte 73/L, monocyte 20/5, fagocyte 1), bacteriological finding was sterile, and protein level 0.46 g/L. The results of a laboratory evaluation were within the normal range, including sedimentation rate, complete blood count, chemistry. Total serum proteins 74,0 g/L, IgG 9,42 g/L, IgA 1.32 g/L, IgM 0.44 g/L, IgE 3.22 kiU/L. Immunological evaluation showed normal total complement, C3 1.38, C4 0.38, CRP 9.7 mg/L, ANA negative, RF 2.4 aCL-IgG 6, aCL-IgM 4, IIF *Borrelia burgdorferi* IgM and IgG negative. The last follow up examination was done in June 2009 in the neurology department which he approached due to a numbness and irritative sensory feelings in his hands and feet, polyarthralgias associated with swelling, insomnia and anxiety. The patient had recovery of low-grade temperature, motor dysfunction, and seizures. As we viewed these symptoms as non-specific, a targeted evaluation was conducted. Control MRI (Figure 4) of the brain in July 2009 showed prominently widened perivascular spaces: in the deep white matter on the bounds between medium and inferior frontal gyrus, periventricular white matter along trigonum of the right

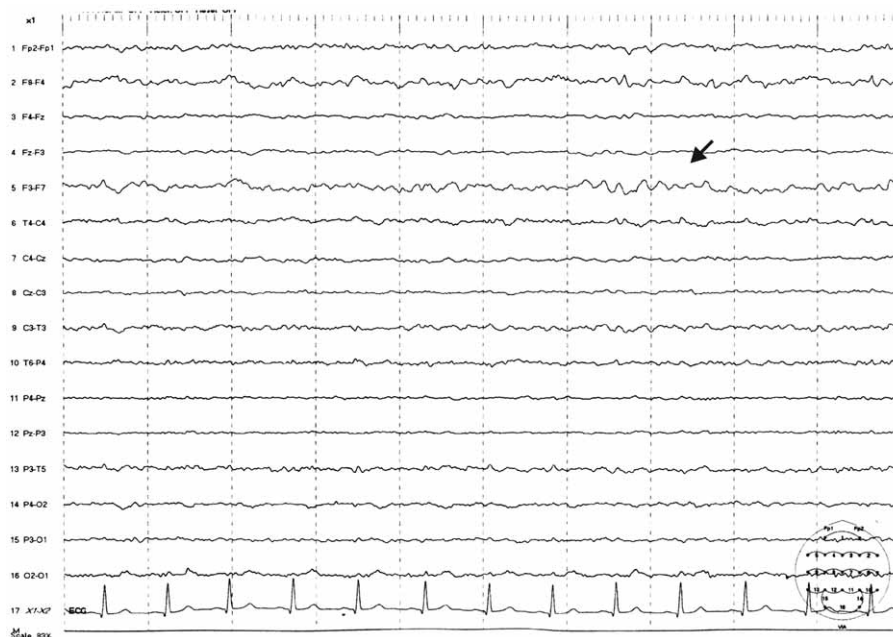


Fig. 5. Follow-up EEG showed diffuse dysrhythmic pattern, predominantly over left anterior region (July, 2009).

lateral ventricle, in the right thalamus and superior frontal gyrus. MRI of the cervical spine did not show any sign of myelopathy. EMNG demonstrated peripheral nerves abnormalities including axonal, sensory and motor peripheral neuropathy presented as distal neuropathy. The last EEG (Figure 5) showed diffuse dysrhythmic pattern more pronounced over the fronto-temporo-central regions. The results of a laboratory evaluation were within the normal range, including sedimentation rate, complete blood count, and chemistry. Serum and intrathecal antibodies against *Borrelia burgdorferi* were not determined at this time, since their long-term persistence is often observed. In the presence of nonspecific long lasting symptoms and in the absence of overt clinical signs suggesting CNS involvement, routine treatment with i.v. ceftriaxone has not been indicated in spite of the fact that these neurologic sequelae influenced his daily activities to a great extent in the post treatment period excessively.

Discussion

Borrelia burgdorferi may cause a wide variety of neurological manifestations^{2,17}. There are an increasing number of patients with chronic LNB. Neurological, cognitive and psychiatric symptoms predominate late in the progression of this disease^{11–13,18}. As these symptoms are sometimes viewed as non-specific and bizarre, the evaluation must be properly targeted. If not, key symptoms may be overlooked and these patients may be misdiagnosed. Once late stage disease exists, it is impossible to prove that *Borrelia burgdorferi* has been eradicated. The affection of the nervous system can be divided into acute and chronic stage. Within several weeks after disease

onset, approximately 15–20% of untreated patients exhibited acute meningo-radicular neuritis (Bannwarth's syndrome), often associated with cranial neuropathy^{19–22}. Months to years later, patients may develop chronic, or late-onset neurologic complications including encephalopathy, encephalomyelitis, seizures⁹, extrapyramidal symptoms such as tremor, chorea²³ or more mild symptoms, with mild memory and mood disturbances, word letter reversals, and spatial disorientation^{10–13}. Major depression, anxiety, panic attacks and catatonia have been reported^{11–14}. Peripheral neuropathy, axonal in nature, both sensory and motor, can present as radiculopathy, plexopathy, distal neuropathy or mononeuritis multiplex^{15,16}. Some patients treated for Lyme disease continue to experience some non-specific symptoms of fatigue, insomnia or psychiatric disorder, so called post borrelia syndrome.

Although the mechanism causing these isolated symptoms in LNB, tremor, seizures and psychotic disturbances can be direct affection of the Bb on neural cells, or to the autoimmune response due to vasculitic changes^{24,25}. If damage to the central and peripheral nervous system exists for more than 6 months, late or chronic neuroborreliosis exist.

We described here one more difficult case of LNB. There was neither history of tick bite nor a bull's eye rash, flu like illness or joint pain. Later there was the development of cognitive symptoms that gradually increased over time. Then the psychiatric and neurological symptoms developed in the course of the illness with an intensification of the cognitive and behavioral symptoms, development of severe tremor, repetitive seizures, myotonia, startle response. Since symptoms were not characteristic for LNB, a long interval between initial infection, appearance of symptoms and effective treatment

elapsed. Psychiatric complaints and tremor were predominant, initially and he was preliminary diagnosed as a psychiatric disorder. Psychiatric disturbances were followed by other neurological symptoms such as myoclonic jerks, paresthesias, headaches and visual disturbances. Diagnosis of the chronic LNB was established later in the course of the disease based upon clinical manifestations, serologic and CSF findings of antibodies specific to *Borrelia burgdorferi*, neuroimaging, electrophysiological studies (EEG and EMNG) and neuropsychological testing. Diagnostic tests for Bb proved positive, showing the presence of serum antibodies (IgG) against *Borrelia burgdorferi* in a titre of 1:2560, determined by indirect immunofluorescence assay. During and after the ceftriaxon and doxycycline treatment the CSF findings normalised. MRI findings corresponded with previous findings on subcortical, demyelinating lesion of the frontal and parietal lobes²⁶, and electrophysiological studies established an axonal degeneration corresponding to peripheral distal, axonal sensor neuropathy^{2,16}. This patient demonstrates that neuropsychiatric disturbances in LNB may closely resemble psychiatric disorder at presentation. The latter diagnosis was entertained on the basis of the tremor and seizures, when the patient was first seen on admission. When all diagnostic tests for Bb proved positive, the diagnosis of LNB was subsequently confirmed by the demonstration of a high antibody titre against *Borrelia burgdorferi*. In retrospect, most of the findings in our patient, were not compatible with the diagnosis of acute LNB. Unusual findings were the prominent tremor²³, seizures⁹, and psychosis^{11–14}, which has rarely been reported in Lyme disease. The presence of multiple neurological and psychiatric symptoms in our patients might imply that there is no specific predilection site for *Borrelia burgdorferi* infection, supporting the previous concept that LNB is a multisystem inflammatory disease¹ associated with vasculitic changes. It is still currently speculated that many of the symptoms seen in chronic LNB are attributable to an inflammatory process rather than active infection. Unfortunately, how such a multisystem lesion is produced is not well understood at the present time. Early, effective treatment is critical. Since the majority of symptoms improved in response to

antibiotic treatment, steroid therapy is not without risk when administered during active infection. In the presence of nonspecific long lasting symptoms without overt clinical signs suggesting CNS involvement, routine treatment with i.v. ceftriaxone was not indicated in spite of the fact that these neurologic sequelae greatly influenced his daily activities in the post treatment period in our patient. Success of the treatment is assessed according to the neurological deficit and normalization of the CSF pleocytosis. Since the serum and intratecal antibodies usually persist for a long period of time in patients with LNB, their further determination is not indicated^{27–29}. Not single positive serological test is solely indicative of the activity of Lyme disease, regardless of the titer of antibodies. The presence of reactive antibodies in serological tests is not sufficient for establishing the diagnosis in the absence of clear clinical symptoms of neuroborreliosis. Serological diagnostics of LNB necessarily involves simultaneous detection of specific antibodies in the serum and CSF as well as assessment of the intratecal synthesis by determination of the antibodies index^{30–33}. As part of an ongoing study to define the clinical spectrum of late LNB, we have identified this patient with uncommon clinical features. Our patient has a chronic form of LNB and displayed neurological symptoms that rarely appear in LNB.

Conclusion

Our study raised clinical interest in a patient with LNB, by revealing the variability of the neurological manifestations of Borreliosis. When neuropsychiatric LNB is a diagnostic possibility, a well focused examination should be performed. Such a tracking system can assist toward clinical diagnosis. This case suggests that LNB should be considered even in patients with rare neuropsychiatric symptoms such as tremor, seizures, and psychosis.

Unrecognized and untreated LNB may progress to severe CNS sequelae, which may have implications for daily activities. In contrast to this, in the presence of non-specific long lasting symptoms without symptoms suggesting CNS involvement antibiotic treatment is encouraged.

REFERENCES

1. ABERER E, J Dtsch Dermatol Ges, 5 (2007) 406. — 2. HALPERIN JJ, Muscle Nerve 28 (2003) 133–43. — 3. PACHNER AR, STEINER I, Lancet Neurol, 6 (2007) 544. — 4. NGGE UR, TANNAPFEL A, TYRING SK, Lancet Infect Dis, 3 (2003) 489. — 5. STEERE AC, Am J Med, 98 (1995) 445. — 6. WULF CH, HANSEN K, STRANGE P, TROJABORG W, J Neurol Neurosurg Psychiatry, 46 (1983) 485. — 7. BOMHOLT A, Arch otolaryngol, 110 (1984) 763. — 8. HINDFELT B, JEPPESON PG, NILLSON B, OLSSON JE, RYBERG B, SÖRNÄS R, Acta Neurol Scand, 66 (1982) 444. — 9. MOURIN S, BONNIER C, BIGAIGNON G, LYON G, Rev Neurol, 149 (1993) 489. — 10. KRUPP LB, MASUR D, SCHWARTZ J, COYLE PK, LANGENBACH LJ, FERNQUIST SK, JANDORF L, HALPERIN JJ, Arch Neurol, 48 (1991) 1125. — 11. FALLON BA, NIELDS JA, Am J Psychiatry, 151 (1994) 157. — 12. FALLON BA, NIELDS JA, PARSONS B, LIEBOWITZ MR, KLEIN DF, J Clin Psychiatry, 54 (1993) 263. — 13. FALLON BA, SCHWARTZBERG M, BRANSFIELD E, ZIMMERMAN B, SCOTTI A, WEBER CA, LIEBOWITZ MR, Psychosomatics, 36 (1995) 295. — 14. GAUDINO EA, COYLE PK, KRUPP LB, Arch Neurol, 54 (1997) 1372. — 15. MYGLAND A, SKARPA T, LJOSTAD U, Eur J Neurol, 11 (2006) 1213. — 16. THAISSETHAWATKUL P, LOGIGIAN E, Reviews J Clin Neurom Dis, 4 (2002) 165. — 17. CORRAL I, QUEREDA C, GUERRERO A, ESCUDEO R, MARTI-BELDA P, Neurologia, 1 (1997) 2. — 18. PACHNER AR, Infectious Disease, 11 (1989) 1482. — 19. DO-TEVALL L, ELIASSON T, HAGBERG L, MANNHEIMER C, Eur J Pain, 3 (2003) 235. — 20. JALLADEAU E, PRADAT P, MAISONOBE T, LEJE J, Rev Neuro, 10 (2001). 1290. — 21. KRISHNAMURTHY K, LIU G, LOGIGIAN E, Muscle nerve, 11 (1993) 1261. — 22. OSCHMANN P, DORN-DORF W, HORNIG C, SCHAFFER C, WELLENSIEK H, J Neurol, 5 (1998) 262. — 23. PICCOLO I, THIELLA G, STERZI R, COLOMBO N, DEFANTI CA, Italian Journal of Neurological Sciences, 19 (1998) 235. — 24. HALPERIN J, SHAPIRO E, LOGIGIAN E, Neurology, 1 (2007) 91. — 25.

KURSAWE H, Fortschr Med, 22 (2002) 33. — 26. FALLON BA, DAS S, PLUTCHOK JJ, TAGER F, LIEGNER K, Van HEERTUM R, Clin Infect Dis, 25 (1997) 57. — 27. STRLE F, Wien Klin Wochenschr, 111 (1999) 911. — 28. RUZIC-SABLJIC E, PODREKA T, MARASPIN V, STRLE F, Int J Antimicrob Agents, 25 (2005) 474. — 29. PFISTER HW, RUPPRECHT TA, Int J Med Microbiol 296 (2006) 11. — 30. DEPIETROPAOLO DI, PO-

WERS JH, GILL JM, FOY AJ, Del Med, 78 (2006) 11. — 31. HAUSER U, LEHNERT G, LOBENTANZER R, WILSKA B, J Clin Microbiol, 35 (1997) 1433. — 32. BUNIKIS J, BARBOUR AG, Med Clin North Am, 86 (2002) 311. — 33. WILSKA B, Vector Borne Zoonotic Dis, 3 (2003) 215.

J. Markeljević

University of Zagreb, Zagreb University Hospital Center, Department of Internal Medicine, Kišpatićeva 12, 10 000 Zagreb
e-mail: Jasenka-markeljevic@gmail.com

TREMOR, EPILEPTIČKI NAPADAJI I PSIHOZA KAO PREZENTIRAJUĆI SIMPTOMI U BOLESNIKA S KRONIČNOM LYME NEUROBORELIJOM

S A Ž E T A K

Lyme boreliozu je ulitistemska bolest koju uzrokuje *Borrelia burgdorferi* (Bb). Neurološki simptomi limfocitni meningoradikukloneuritis (Bannwart's syndrome), kranijalni neuritis (II,III,IV,V,VI), encefalitis, transverzni mijelitis nalaze se u oko 10% bolesnika u drugom stadiju bolesti. U kroničnom stadiju, nekoliko mjeseci ili godina nakon inicijalne infekcije, mogu se javiti neurološke komplikacije i to encefalomijelitis, epileptičke krize, kognitivni deficiti, periferna neuropatija i psihijatrijski poremećaji kao depresija, anksioznost, panične atake, katatonija, psihoza i dr. Neki bolesnici imaju simptome opće slabosti, nesanicu ili psihičke simptome u tzv. »post borrelia sindromu«. Ovdje opisujemo bolesnika sa trijadom neobičnih simptoma kronične Lyme neuroborelioze uključujući tremor, epileptičke napadaje i psihozu. Evaluacija bolesnika obuhvatila je anamnezu, neurološki pregled, neuroimaging, serologiju seruma i cerebrospinalnog likvora, EEG i EMNG. Bolesnik je na terapiju ceftriaxonom i doxycyclinom intravenski reagirao brzim kliničkim i funkcionalnim oporavkom. Ipak, imao je multiple sistemske i neurološke komplikacije koje su utjecale na njegove svakodnevne aktivnosti u razdoblju nakon tretmana. Naglasak je stavljen na atipičan nastup i evoluciju simptoma bolesti, poteškoće u postavljanju dijagnoze, rani tretman i neizvjesnost u pogledu komplikacija nakon tretmana. U bolesnika s nespecifičnim, dugotrajnim simptomima Lyme neuroborelioze, u odsutnosti drugih kliničkih znakova koji bi ukazivali na zahvaćenost CNS-a, rutinski tretman ceftriaxonom intravenski nema terapijskog efekta.