

Fragile X-premutation tremor/ataxia syndrome (Fxtas) in a young woman: clinical, genetics, Mri and 1H-Mr spectroscopy correlates

Šarac, Helena; Henigsberg, Neven; Markeljević, Jasenka; Pavliša, Goran; Hof, Patric R.; Šimić, Goran

Source / Izvornik: *Collegium Antropologicum*, 2011, 35, 327 - 332

Journal article, Published version

Rad u časopisu, Objavljena verzija rada (izdavačev PDF)

Permanent link / Trajna poveznica: <https://urn.nsk.hr/urn:nbn:hr:105:321653>

Rights / Prava: [In copyright](#) / [Zaštićeno autorskim pravom](#).

Download date / Datum preuzimanja: **2024-07-15**



Repository / Repozitorij:

[Dr Med - University of Zagreb School of Medicine Digital Repository](#)



Fragile X-Premutation Tremor/Ataxia Syndrome (Fxtas) in a Young Woman: Clinical, Genetics, Mri and ¹H-Mr Spectroscopy Correlates

Helena Šarac¹, Neven Henigsberg², Jasenka Markeljević³, Goran Pavliša⁴, Patric R. Hof⁵ and Goran Šimić⁶

¹ University of Zagreb, School of Medicine, Zagreb University Hospital Centre, Department of Neurology and Croatian Institute for Brain Research, »Neuron« Diagnostic Centre, Zagreb, Croatia

² University of Zagreb, School of Medicine, Croatian Institute for Brain Research, Department of Psychiatry, Zagreb, Croatia

³ University of Zagreb, School of Medicine, Zagreb University Hospital Centre, Department of Internal Medicine, Zagreb, Croatia

⁴ University of Zagreb, School of Medicine, Croatian Institute for Brain Research, Diagnostic Centre »Neuron«, Department of Radiology, Zagreb, Croatia

⁵ Department of Neuroscience, Mount Sinai School of Medicine, New York, NY, USA

⁶ University of Zagreb, Croatian Institute for Brain Research, Department of Neurodegenerative Disorders, Zagreb, Croatia

ABSTRACT

It is generally thought that fragile X-associated tremor/ataxia syndrome (FXTAS) represents a late-onset neurodegenerative disorder occurring in male carriers of a premutation expansion (55–200 CGG repeats) in the fragile X mental retardation 1 (FMR1) gene. However, several female patients with FXTAS have also been reported recently. Here, we describe a 23-year old woman with positive family history of mental retardation and autism who presented clinically with action tremor, ataxia, emotional disturbances and cognitive dysfunction. Magnetic resonance imaging (MRI) of the brain showed diffuse cortical atrophy, while ¹H-MR spectroscopy (MRS) revealed decreased levels of N-acetylaspartate (NAA) in the cerebellum, basal ganglia, and pons. Genetic testing confirmed heterozygous FMR1 gene premutation of 100 CGG repeats in the abnormal allele and 29 CGG repeats in the normal allele. We concluded that FXTAS may be an under-recognized disorder, particularly in women.

Key words: FMR1 gene, fragile X premutation, tremor, cerebellar ataxia, cognitive impairment, genetics, MRI, ¹H-MR spectroscopy

Introduction

Fragile X tremor/ataxia syndrome (FXTAS) is a progressive neurological condition that has been recognized in a subgroup of adult older than 50 years of age carriers of the FMR1 (fragile site mental retardation 1 gene) premutation (55–200 repeats)^{1,2}. Until recently, premutations had only been associated with premature ovarian failure in 21% of carriers³. The main clinical feature of this new syndrome is a progressive cerebellar ataxia that may be accompanied by intention tremor. These signs were chosen as clinical inclusion criteria by Jacquemont et al.². Other clinical features include short-term memory loss, executive function deficits, gradual cognitive decline leading to dementia^{5–7}, parkinsonism and autonomic

dysfunction^{1,2,4}, peripheral neuropathy, loss of vibration and tactile sensation and reflexes in the distal lower extremities², and emotional problems and psychiatric symptoms including anxiety, mood lability, and depression^{2,8–12}. Traditionally thought to affect men older than 50 years in known fragile X families, FXTAS syndrome affect women as well, with only a few case studies reported^{11–15}. The second X chromosome in women may be protective against FXTAS^{13,14}. Premutation carriers have slightly reduced levels of the FMR1 protein product (FMRP), but dramatically (two- to eightfold) elevated levels of FMR1 messenger RNA (mRNA)¹⁶. Results of previous studies on the prevalence of FMR1 premutation

alleles within populations with movement disorders have not been consistent³. Significant proportions of preutation carriers were found in three cohorts of male patients with spinocerebellar ataxia (2.2%, 4.1%, and 5%^{17–19}), in contrast to patients with essential tremor²⁰, atypical parkinsonism²¹, and multiple system atrophy (MSA)^{3,22} with which FXTAS is very unlikely to be confused. Brunberg et al.²³ and Jacquemont et al.¹² reported associated neuroimaging findings which include global brain atrophy and white matter disease, with a characteristic enhancement of T2 signal intensity in the middle cerebellar peduncles (MCP). Further studies of the clinical, neuroimaging and genetic effects of the preutation allele in the both female and male carriers are therefore needed.

Case Report

Patient is a 23-years old female who experienced onset of social phobia at age 20 years when she lost her job. Autism was followed a months later by difficulties in performing fine motor skills, progressive left hand numbness and tremor, ataxia, reduced psychomotor activity and disinhibition. In the family history, her brother suffered from similar symptoms in childhood, and died at 22 years of age without specific diagnosis.

Severe tremors and ataxia developed in her 23 resulting in frequent falling. Levodopa was prescribed for her tremor and bradikinesia and was found to be of minor helpful. On examination, she had left hand tremor at rest, normal eye movement, dysarthria, nonfluent speech, amimia, bradyphrenia, dysarthria, retarded motor activity, freezing episodes, and difficulties initiating movements. Tandem walking demonstrated ataxia, and gait was mildly broad based. Postural stability was markedly impaired. Tone was increased, while power and reflexes were normal. She did not complain of urinary incontinence and had no clinical evidence of autonomic failure. These symptoms responded partially to low-dose levodopa treatment. Neuropsychological assesment showed moderate generalized cognitive decline from the patient premorbid level. The first electroencephalogram (EEG) examination revealed dysrhythmic pattern with paroxysms of slow variant spike and wave complexes. Electromyogram and nerve conduction studies showed no evidence of diffuse polyneuropathy. Cognitive evoked potentials, P300 visual potential was normal in the counting processing, and abnormal in the motoric reactions. P300 auditory potential showed significant disturbances in conscious processing. Spectral positron emission computed tomography (SPECT) revealed normal cerebral and cerebellar perfusions. Routine blood processing showed significant hypercholesterolemia (7.8 mol/L) and LDL(6.0 mmol/L). Urin analysis revealed nonspecific urine neutral amino acids, including histidine, serine, taurine, glutamine, alanine, glutamic acid, β-aminobutyric acid, phenylalanine, valine, and leucine. Cerebrospinal fluid (CSF) findings were within normal range.

Structural and functional imaging results were not fully consistent with the diagnosis of FXTAS in the pres-

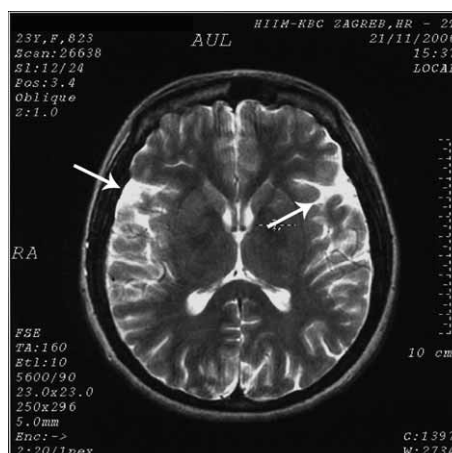


Fig. 1. Twenty-three-year-old woman with FXTAS. Head MR image of the patient using FLAIR sequences shows global brain atrophy.

ent case. Initial MRI scans of the brain at 1.5 T (Siemens) showed premature, global brain atrophy (Figure 1), high intensity signal in the pons (Figure 2), and deep cerebellar white matter hyperintensity signal (Figure 3). There were neither thinning of the oblique transverse diameters of either MCPs (Figure 4) nor white matter changes in the cerebrum. ¹H-MR spectroscopic studies were performed with a point-resolved spectroscopic sequence on a 2.0 T MR imager (GE Medical Systems) at the Croatian Institute for Brain Research, University of Zagreb. Spectra were obtained and analyzed by one observer (G.P). We used metabolite ratios found in the literature²⁴ for comparison to our results. Peak area ratios of NAA/Cr, NAA/Cho, Cho/Cr, Glx/Cr and mL/Cr in the occipital white matter, globus pallidus, pons, and cerebellar white matter were calculated. The first spectrum was obtained from the globus pallidus and showed peak ratios decreases of 40% for NAA/Cr, 20% for NAA/Cho and 10% for NAA/Cr, while mL increased by 30% in comparison to healthy control (Figure 5). The second spec-

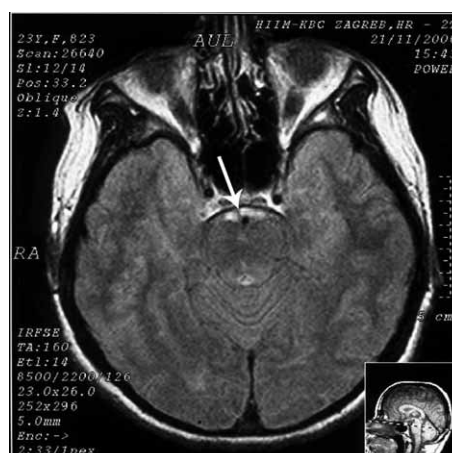

Fig. 2. T2-weighted MR image demonstrating high intensity signal in the basis pontis.

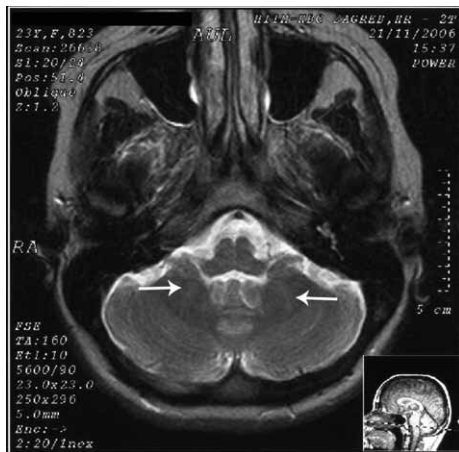

Fig. 3. T2 weighted MR images showing a less prominent signal in the cerebellar deep white matter compared to the pons.

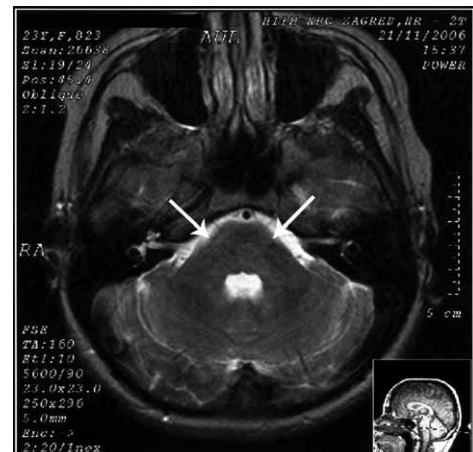

Fig. 5. Magnetic resonance spectroscopy (MRS) of the left globus pallidus demonstrating decreased NAA/Cr (40%), decreased NAA/Cho ratio (10%) and decreased Cho/Cr ratio (10%) (in comparison to control).

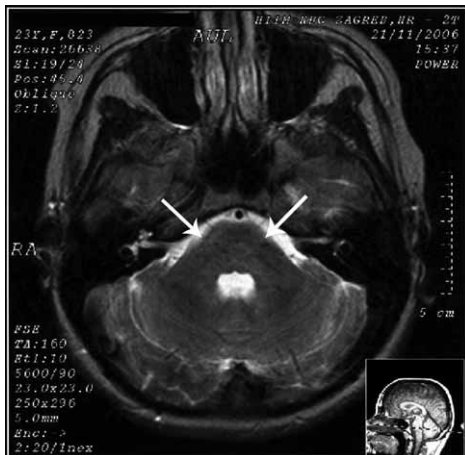

Fig. 4. T2 weighted images showing no atrophy of the middle cerebellar peduncle.

trum was obtained from pons and showed peak ratios decrease of 15% for NAA/Cr, no difference from normal values for NAA/Cho, while mL increased by 10% (Figure 6). The third spectrum was obtained from cerebellar white matter and showed peak ratios decrease of 40% for NAA/Cr, while NAA/Cho, Cho/Cr and mL were normal (Figure 7).

Given the patient's presentation with tremor, ataxia, cognitive impairment, autism, behavioral issues including poor eye contact, anxiety, selective mutism, attention problem and positive family history whereas her brother who died young with ataxia, psychiatric problems, and other problems suggestive of hereditary neurological disease, we suspected FXTAS and requested FMR1 gene analysis.

Methods

Testing for abnormal expansion of the CGG repeat in the FMR-1 gene was performed by using polymerase

chain reaction (PCR) amplification with Expand Long enzyme and Southern blot analysis of restriction endonuclease digested genomic DNA from leukocytes. High resolution techniques of the selection, such as capillary electrophoresis of products and visualisation by using fluorescent marked novice are performed^{25,26}. Visualisation of reproduced sequences is performed by using the Southern blot method of the hybridisation. This method enable detection of the triplet expansion in the fragile X syndrome. Detection of the hybridisation probes on the membrane is performed by using DIG Wash and Block

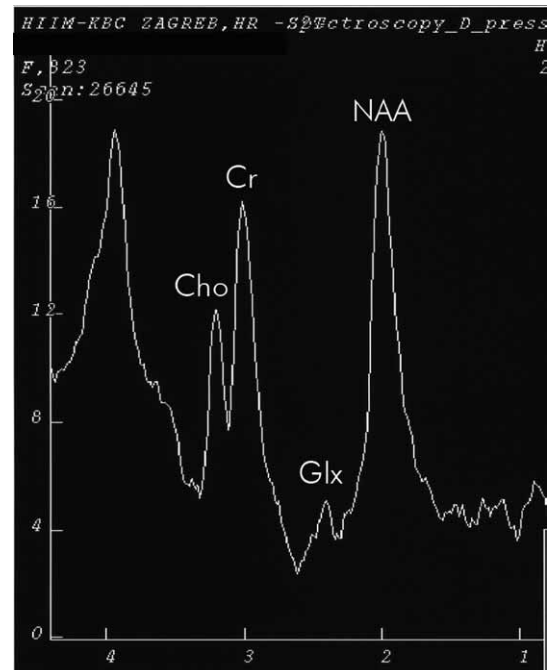


Fig. 6. MRS of the basis pontis shows reduced NAA/Cr ratio (15%), normal NAA/cho ratio, increased mI ratio (10%).

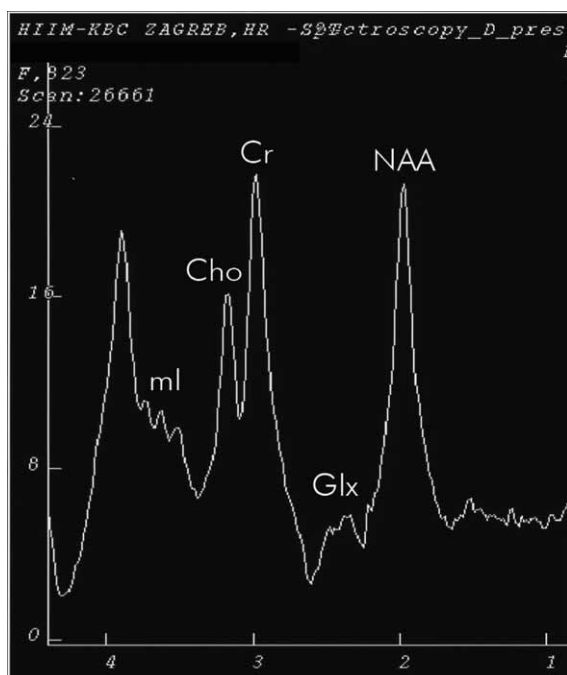


Fig. 7. Metabolite ratio of the cerebellar deep white matter revealed decreased NAA/cr ratio (40%), and normal NAA/Cho and Cho/Cr ratio.

Buffer Set (Roche), antibody solution Anti-Digoxigenin-AP (Roche) and CDP-Star substrate (Roche). CGG repeat region of the FMR1 gene was analysed restrictive endonuclease to digest the genomic DNA and the Dig-5(CGG) (Roche) probe, which contains sequences homologous to the FMR1 gene.

Results

DNA analysis revealed that our patient was a FMR1 premutation carrier with 100 CGG repeats in the abnormal allele and 29 CGG repeats in the normal allele. The accuracy of sizing was consistent between both methods, PCR and Southern blot analysis.

Discussion

FXTAS is generally thought to affect men^{11–15}, women being considered to be protected against the development of the neurologic symptoms by the second X chromosome^{13,14}. Recent reports document that isolated women carriers of the expanded FMR1 gene have FXTAS with less severe neuropsychiatric symptoms^{12,13}. Female premutation carriers usually present with psychiatric problems, such as social phobia, anxiety²⁷.

Our patient who was believed to have some metabolic disorder due to tremor, ataxia, cognitive symptoms and presence of high concentrations of urine amino acids, was diagnosed with FXTAS syndrome on the basis of clinical symptoms, neuroimaging findings including MRI, MRS and genetic testing.

In contrast to previous reports which described less severe neurologic disturbances in women later in life, we report an isolated case of early-onset FXTAS in a young woman, who progressively developed severe neurological disturbances. Perhaps the abnormally long CGG repeat of 100 repeats played an important role in making neurologic symptoms more manifest. Cohen et al.²⁸ reported a correlation between CGG repeat length and reductions in IQ and increased ventricular volume, in patients with premutation.

Al-Hinti et al.²⁹ reported that abnormally long 103-CGG repeat correlated with patient's symptomatic severity. FXTAS arises when neuropsychiatric disturbances are associated with abnormalities visible on MRI^{3,23,29}. MRI usually reveals moderate cerebral atrophy, minimal changes in the pons and deep cerebellar white matter, and enlargement of the fourth ventricle. Our case showed no high T2 signal and no atrophy in the MCPs.

In the absence of the characteristic high T2 signal intensity in the MCP, the diagnosis of the definite FXTAS cannot be established according to the clinical classification criteria of Jacquemont et al.² and Brunberg et al.²³ Radiologic findings in the MCP are thought to be specific for the FXTAS and are related to the spongiform changes observed in the same regions²³. However, characteristic brain MRI high intensity signal in the MCP is not always present in women or may be unremarkable¹². Nonetheless, the less prominent abnormalities in the deep white matter of the cerebellum and pons in the absence of the bilateral signal changes in the MCPs in our patient is fully correlated with findings reported from Al-Hinti et al. in one woman with fragile X premutation with cognitive impairment, tremor, and history of premature ovarian failure²⁶. Recently Adams et al.²⁹ have found, using volumetric brain changes in women with FXTAS, less pronounced reductions of cerebellar volume and lower incidence of involvement (symmetric high T2 signal) of the MCP (13%) affected by FXTAS compared to affected men (58%). These authors also observed significant correlation between increased length of CGG repeat, severity of FXTAS symptoms, and reduced cerebellar volume. However, prediction of the severity of the symptoms of fragile X syndrome is limited³⁰.

Ginestroni et al.³¹ found decreased pontine NAA/Cr ratio in one of three patient with FXTAS by using ¹H-MR spectroscopy of the brainstem and cerebellum. In our patient the spectra was the most suggestive of multiple system atrophy^{32,33}. Recent ¹H-MRS studies of the striatum revealed reduced NAA/Cr ratio in MSA patients and the preserved NAA/Cr ratio in Parkinson's disease (PD) patients. The reduced NAA/Cr ratio probably reflects striatal neuronal loss³². Watanabe et al. reported that the NAA/Cr in MSA patient shows a significant reduction in the putamen and the pontine base, as well as in the cerebral white matter in long duration cases, even from the early phase of the disease, in patients who show no ataxic symptoms or parkinsonism, or in those with unremarkable MRI findings³³. Furthermore, our patient is an example of a more difficult case because additional spectro-

scopic metabolite abnormalities were detected. Slightly reduced NAA/Cr ratio (15%) was detected in the pons, but the same parameter was very much decreased in the globus pallidus (40%) and cerebellar white matter (40%). Because NAA is considered a neuronal marker, our results of decreased NAA/Cr in the globus pallidus, cerebellar white matter, and pons suggest loss of neuronal viability in the course of significant degeneration in these regions. Also, we found moderately increased ml/Cr ratio in the globus pallidus (30%) and slightly elevated pontine ml (a glial marker) level. We found no excess of Cho/Cr ratio suggesting that neither axonal degeneration nor demyelination of subcortical white matter occurred. Ginestroni et al. also reported decreased level of NAA in the pons only in one of three patients³⁰.

Although FXTAS syndrome has already been documented in women^{12–14}, no *in vivo* MRS studies for the detection and quantification of neurodegenerative changes in FXTAS have been performed in such a young female patient. Despite lacking pathologic confirmation, clinical diagnosis of FXTAS was firmly established by using the diagnostic criteria^{2,4,12}, including MRI, and by additional investigations such as neuropsychology examination, EEG, cognitive evoked potentials and ¹H-MR spectroscopy. The final diagnosis is established by using genetic testing. Although neuropsychological investigation showed significant functional impairment of frontal, parietal, and temporal lobes, and of subcortical structures, such as basal ganglia, these findings only suggest the diagnosis of FXTAS, but do not provide an explanation of mechanisms by which the brain is affected in FXTAS. Our report provides unusual case of young woman, carrier of the fragile X premutation, who exhibited severe neurological disturbances. Practitioners should be aware of FXTAS in any woman presenting with a triad of ataxia, tremor, and cognitive impairment, particularly if positive

family history exists. Atrophy and spectroscopic metabolic changes in FXTAS are entirely consistent with the pathologic pattern of MSA patients³², but differ to some extent from those of olivopontocerebellar atrophy (OPCA) and dementia³³.

Conclusion

Carriers of premutation alleles (55–200 CGG repeats) of *FMR1* are now being identified with one or more clinical syndromes, including mild cognitive dysfunction, behavioral deficits, and a neurodegenerative disorder not only among older adult but also in young carriers. Awareness of these syndromes is important for clinicians, especially neurologists and psychiatrists when they encounter patients with tremor, ataxia, parkinsonism, and cognitive dysfunction. The clinical assessment in such patients requires obtaining clinical examination, specific neuroimaging studies, including brain imaging and molecular genetic diagnostic tools. Metabolic screening tests such as quantitative studies for amino acids in blood and urine, plasma lactate, ammonia, urine analysis for amino acids should also be considered upon consultation with a geneticist. Individuals for whom fragile X syndrome testing should be considered include mental retardation of unknown etiology, autism or autism spectrum disorder—not otherwise specified or Asperger syndrome, women with premature ovarian dysfunction ≤40 years of age of unknown etiology, learning disability, behavioral issues including poor eye contact, anxiety, selective mutism, attention problems, hyperactivity, men and women who experience primarily late-onset or early-onset intention tremor and cerebellar ataxia of unknown origin, especially if they have a positive family history of movement disorders or fragile X syndrome and developmental delay.

H. Šarac

»Neuron« Diagnostic Centre, Croatian Institute for Brain Research, Šalata 12, 10 000 Zagreb, Croatia
e-mail: helenasarac@hi.t-com.hr

REFERENCES

- HAGERMAN RJ, LEECHEY M, HEINRICHS W, TASSONE F, WILSON R, HILLS J, GRIGSBY J, GAGE B, HAGERMAN PJ, *Neurology*, 57 (2001) 127. — 2. JACQUEMONT S, HAGERMAN RJ, LEEHEY M, GRIGSBY J, ZHANG L, BRUMBERG JA, GRECO C, *Am J Hum Genet*, 72 (2003) 869. — 3. KAMM C, HEALY DG, QUINN NP, WULLNER U, MOLLER JC, SCHOLS L, GESER F, BURK K, BORGLUM AP, PELLESIA MT, TOLOSA E, *Brain*, 128 (2005) 1855. — 4. BERRY-KRAVIS E, LEWIN F, WU J, LEEHEY M, HAGERMAN R, HAGERMAN P, *Ann Neurol*, 53 (2003) 616. — 5. GRIGSBY J, BREGA AG, JACQUEMONT S, LOESCH DZ, LEEHEY MA, GOODRICH GK, HAGERMAN RJ, EPSTEIN J, WILSON R, COGSWELL JB, JARDINI T, TASSONE F, HAGERMAN PJ, *J Neurol Sci*, 248 (2006) 227. — 6. GRIGSBY J, LEEHEY MA, JACQUEMONT S, BRUNBERG JA, HAGERMAN RJ, WILSON R, EPSTEIN JH, GRECO CM, TASSONE F, HAGERMAN PJ, *Cogn Behav Neurol*, 19 (2006) 165. — 7. BACALMAN S, FARZIN F, BOURGEOIS JA, COGSWELL J, GOODLIN-JONES BL, GANE LW, GRIGSBY J, LEEHEY MA, TASSONE F, HAGERMAN RJ, *J Clin Psychiatry*, 67 (2006) 87. — 8. CORNISH KM, KOGAN C, TURK J, MANLY T, JAMES N, MILLS A, DALTON A, *Brain Cogn*, 57 (2005) 53. — 9. FRANKE P, LEBoyer M, GANISCKE M, *Psychiatry Res*, 80 (1998) 113. — 10. HESSL D, TASSONE F, LOESCH DZ, BERRY-KRAVIS E, LEECHEY MA, GANE LW, BARBATO I, LEWIN F, WEINBERG D, HAGERMAN PJ, HAGERMAN RJ, *Am J Med Genet Neuropsychiatr Genet*, 139 (2005) 115. — 11. QWYER JP, CLABBY C, CROWN J, BARTON DE, HUTCHINSON M, *Neurology*, 65 (2005) 331. — 12. HAGERMAN RJ, LEAVITT BR, FARZIN F, JACQUEMONT S, RECO CM, BRUNBERG JA, TASSONE F, HESSL D, HARRIS SW, ZHANG L, JARDINI T, GANE LW, FERRANTI J, RUIZ L, LEEHEY MA, GRIGSBY J, HAGERMAN PJ, *Am J Hum Genet*, 74 (2004) 1051. — 13. BERRY-KRAVIS E, POTANOS K, WEINBERG D, ZHOU L, GOETZ CG, *Ann Neurol*, 57 (2005) 144. — 14. JACQUEMONT S, ORRICO A, GLLI L, SAHOTA PK, BRUNBERG JA, ANICHINI C, LEEHEY M, SCHAAEFFER S, HAGERMAN RJ, HAGERMAN PJ, TASSONE F, *J Med Genet*, 42(2) (2005) 14. — 15. ZUHLKE C, BUDNIK A, GEHLKEN U, DALSKI A, PURMANN S, NAUMANN M, SCHMIDT M, BURK K, SCHWINGER E, *J Neurol*, 251 (2004) 1418. — 16. TASSONE F, HAGERMAN RJ, TAYLOR AK, GANE LW, GODFREY TE, HAGERMAN PJ, *Am J Hum*

- Genet, 74 (2004) 805. — 17. BRUSSINO A, GELLERA C, SALUTO A, MARIOTTI C, ARDUINO C, CASTELLOTTI B, CAMERLINGO M, DE ANGELIS V, ORSI L, TOSCA P, MIGONE N, TARONI F, BRUSCO A, Neurology, 64 (2005) 145. — 18. VAN ESCH H, DOM R, BEX D, SALDEN I, CAECKEBEKE J, WIBAIL A, BORGHGRAEF M, LEGIUS E, FRYNS JP, MATTHIJS G, Eur J Hum Genet, 13 (2005) 121. — 19. MACPERSON J, WAGHORN A, HAMMANS S, JACOBS P, Hum Genet, 112 (2003) 619. — 20. GARCIA AROCENA D, LOUIS ED, TASSONE F, GILLIAM TC, OTTMAN R, JACQUEMONT S, HAGERMAN PJ, Mov Disord, 19 (2004) 930. — 21. TAN EK, ZHAO Y, PUONG KY, LAW HY, CHAN LL, YEW K, TAN C, SHEN H, CHANDRAN VR, TEOH ML, YIH Y, PAVANNI R, WONG MC, Neurology, 63 (2004) 362. — 22. YABE I, SOMA H, TAKEI A, FUJIKI N, SASAKI H, J Neurol, 251 (2004) 1411. — 23. BRUNBERG JA, JACQUEMONT S, HAGERMAN RJ, BERRY-KRAVIS E, GRIGSBY J, LEEHEY M, TASSONE F, BROWN WT, GRECO C, HAGERMAN PJ, Am J Neuroradiol, 23(10) (2002) 1757. — 24. ROSS B, DANIELSEN ER, Magnetic Resonance Spectroscopy Diagnosis of Neurologic Diseases (Marcel Dekker, New York, 1999). — 25. ROUSSEAU F, HEITZ D, BIANCALANA V, N Eng J Med, 325 (1991) 1673. — 26. VLAŠIĆ-TANASKOVIĆ J, SERTIĆ J, Biochemica Medica, 3-4 (2004) 100. — 27. ALLINGHAM-HAWKINS D, BABUL-HIRJI R, CHITAYAT D, HOLDEN JJ, YANG KT, LEE C, HUDSON R, GORWILL H, NOLIN SL, GLICKSMAN A, JENKINS EC, BROWN WT, HOWARD-PEEBLES PN, BECCHI C, CUMMINGS E, FALLON L, SEITZ S, BLACK SH, VIANNA-MORGANTE AM, COSTA SS, OTTO PA, MINGRONI-NETTO RC, MURRAY A, WEBB J, VIEN F, Am J Med Genet, 83 (1999) 322. — 28. COHEN S, MASYN K, ADAMS J, HESSL D, RIVERA S, TASSONE F, BRUNBERG J, DECARLI C, Neurology, 67 (2006) 1426. — 29. ADAMS BA, ADAMS PE, NGUYEN D, BRUNBERG JA, TASSONE F, ZHANG W, KOLDEWYN K, RIVERA SM, GRIGSBY J, ZHANG I, DECARLI C, HAGERMAN PJ, HAGERMAN RJ, Neurology, 69 (2007) 851. — 30. SHERMAN S, PLETCHER BA, DRISCOLL DA, Genetic in Medicine, 7(8) (2005) 584. — 31. GINESTRONIA, GUERRINI I, DELLA NAVE R, TESSA C, CELLINI E, DOTTI MT, BRUNORI P, DE STEFANO N, PIACENTINI S, MASCALCHI M, Am J Neuroradiol, 28 (2007) 486. — 32. AOTSUKA A, SHINOTOH H, HATTORI T, Nippon Rinsho, 55(1) (1997) 249. — 33. WATANABE H, FUKATSKU H, KATSUNO M, SUGIURA M, HAMADA K, OKADA Y, HIRAYAMA M, ISHIGAKI T, SOBUE G, J Neurol Neurosurg Psychiatry, 75(1) (2004) 103. — 34. ERNST T, CHANG L, MELCHO R, MEHRINGER CM, Magn Reson Med, 32 (1994) 110.

FRAGILNI X-VEZANI TREMOR/ATAXIA SINDROM (FXTAS) U MLADE ŽENE: KLINIČKA, GENETSKA, MRI I ¹H-MR SPEKTROSKOPSKA KORELACIJA

SAŽETAK

Poznato je da X-vezani tremor/ataxia sindrom (FXTAS) predstavlja neurodegenerativnu bolest s kasnim nastupom prvenstveno kod muških mosilaca premutacije (55–200 CGG ponavljanja) na FMR 1 genu (fragile X mentalna retardacija). Ipak postoji nekoliko opisanih slučajeva oboljelih žena sa FXTAS. Opisujemo 23-godišnju djevojku sa pozitivnom obiteljskom anamnezom mentalne retardacije i autizma sa simptomima tremora, ataksije, emocionalne nestabilnosti i kognitivnih disfunkcija. Magnetska rezonancija (MRI) mozga otkrila je difuznu kortikalnu atrofiju, dok je spektroskopija magnetskom rezonancijom (MRS) pokazala sniženu razinu N-acetilaspargata (NAA) u cerebelumu, bazalnim ganglijima i ponsu u odnosu na nalaze zdravih pojedinaca. Genetsko testiranje potvrdilo je heterozigotnu premutaciju FMR 1 gena sa 100 ponavljanja u abnormalnom alelu i 29 CGG ponavljanja u normalnom alelu. Zaključujemo, da bi FXTAS mogla biti nedovoljno prepoznata bolest, posebno u žena.