

Pulmonary myelolipoma containing osseous tissue: an unexpected finding at autopsy

Mašić, Silvija; Vučić, Majda; Seiwerth, Sven

Source / Izvornik: **Respiratory Medicine Case Reports**, 2017, 22, 254 - 256

Journal article, Published version

Rad u časopisu, Objavljena verzija rada (izdavačev PDF)

<https://doi.org/10.1016/j.rmcr.2017.09.008>

Permanent link / Trajna poveznica: <https://um.nsk.hr/um:nbn:hr:105:992157>

Rights / Prava: [In copyright](#) / [Zaštićeno autorskim pravom](#).

Download date / Datum preuzimanja: **2025-03-31**



Repository / Repozitorij:

[Dr Med - University of Zagreb School of Medicine
Digital Repository](#)





Case report

Pulmonary myelolipoma containing osseous tissue: An unexpected finding at autopsy

Silvija Mašić^{a,*}, Majda Vučić^b, Sven Seiwerth^{c,d}^a Clinic for Oncology and Nuclear Medicine, Sestre Milosrdnice Clinical Hospital Centre, Vinogradska cesta 29, Zagreb, Croatia^b Department of Pathology, Sestre Milosrdnice Clinical Hospital Centre, Vinogradska cesta 29, Zagreb, Croatia^c Institute of Pathology, University of Zagreb, Šalata 10, Zagreb, Croatia^d Department of Pathology, Clinical Hospital Centre Rebro, Kišpatičeva 12, Zagreb, Croatia

ARTICLE INFO

Article history:

Received 4 September 2017

Received in revised form

12 September 2017

Accepted 12 September 2017

Keywords:

Lung

Myelolipoma

Benign

Autopsy

ABSTRACT

Pulmonary myelolipoma is a very rare benign tumor composed of mature adipose tissue and hematopoietic elements such as erythroid, myeloid and megakaryocytic. It usually represents accidental finding during autopsy or chest imaging, since most cases are asymptomatic. Larger masses can lead to hemorrhage, chest pain and chest organ compression. We present a case of incidental finding of pulmonary myelolipoma during the autopsy of an 83-year old woman who died of abdominal aortic rupture. In the right lower lung lobe, solitary, well-circumscribed yellow-brown nodule which was 3 cm in its longest diameter was found. Pathohistological analysis revealed tumor composed of mature adipose tissue and hematopoietic cells (myeloid cells, megakaryocytes, erythroid cells) with fragments of mature bone tissue. Differential diagnosis of pulmonary myelolipoma includes lipoma, liposarcoma, hamartoma, phlebangioma, teratoma and extramedullary hematopoiesis. In majority of cases, tumor removal is not necessary, however, larger lesions should be surgically removed. No cases of malignant transformation or recurrence have so far been reported in the literature.

© 2017 Published by Elsevier Ltd. This is an open access article under the CC BY-NC-ND license (<http://creativecommons.org/licenses/by-nc-nd/4.0/>).

1. Introduction

Myelolipoma is a lesion composed of mature fatty tissue and hematopoietic elements [1–11]. It represents a rare finding, especially in sites other than adrenal gland, such as lungs, mediastinum, thoracic spine, kidney, presacral and perirenal area, stomach, thyroid gland, liver, nasal cavity, bone, bronchi [1–5,7–10]. Its behavior is benign in nature [1], which usually results in accidental revelation of the tumor during autopsy or during imaging procedures [1,3,6]. Due to usually been asymptomatic, its incidence is hard to establish, but is considered to be 0.08%–0.2% [1]. Literature reported 3% of cases to be present in thoracic region [2]. Intrapulmonary myelolipoma is especially rare with only 10 cases so far reported in the literature according to Xu et al. [7]. It appears mostly in adult male patients from the of age 45–81 [10]. We describe a case of a patient who died of consequences of abdominal aortic rupture, while pulmonary myelolipoma was incidental finding.

2. Case report

An 83-year old female patient was brought to hospital emergency service due to chest and abdominal pain with severe hypotension. Clinical examination excluded possible myocardial infarction as primary diagnosis due to normal ECG and no change in cardiac enzymes levels. The patient was then admitted to intensive care unit under diagnosis of ileus concomitant with hypovolemic and septic shock. Shortly after the admission, the patient's condition deteriorated to feculent vomiting and cardiorespiratory arrest. Resuscitation was performed, but unsuccessfully.

Autopsy was performed 60 hours after patient's death. Findings of the autopsic examination revealed pallor of the entire body skin. Further, fibrosis and hypertrophy of myocardial muscle was found. Also, signs of pulmonary and cerebral oedema were present. In the left hypochondrium, hematoma 6 cm in its longest diameter was revealed. Liver cyanosis with fatty changes and splenic cyanosis were observed. Both kidneys were normal in size and shape, the right displaying a single cyst (0,5 cm) and the left being surrounded by hematoma. Also, chronic gastric ulcer 1 cm in longest diameter was found, demonstrating no signs of acute hemorrhage. Arteries were severely atherosclerotically changed, which led to abdominal

* Corresponding author.

E-mail addresses: silvijamasic57@gmail.com (S. Mašić), majda.vucic@kbcsm.hr (M. Vučić), sven.seiwerth@mef.hr (S. Seiwerth).

aortic rupture which was 4.5 cm in diameter and was identified as the cause of lethal outcome in our patient. Besides pulmonary cyanosis, in the right lower lobe, well-circumscribed yellow-brown nodule, which was 3 cm in size and appeared calcified when cutting the tissue, was found (Fig. 1).

Routine hematoxylin & eosin staining of the nodule revealed a lesion composed of mature adipose tissue and hematopoietic cells (myeloid cells, megakaryocytes, erythroid cells) with fragments of mature bony tissue (Fig. 2) suggesting the diagnosis of pulmonary myelolipoma. Adipose tissue involved around 50% of the lesion. No foci of extramedullary hematopoiesis have been found in liver and splenic parenchyma.

3. Discussion

Etiology of myelolipoma is still not entirely clarified. More theories concerning formation of this lesion exist, reporting possible myelolipoma development from embryonic mesenchymal

cells originating from adrenal gland, emboli derived from hematogenous bone marrow, reticuloendothelial cell metaplasia and proliferation of hematopoietic stem cells [1–4,6,8].

Usually no symptoms are related to myelolipoma [7], however, according to available literature hemorrhage and compression of adjacent structures can occur. Cases of pulmonary lesions have been described as being related to lumbar spine pain, fever, cough, pneumonia, bronchiectasis, pulmonary atelectasis [3,7,9]. Other locations were related to chest pain, back pain, renal pain, dysuria [6,9,11]. Also, in patients with cortisol overproduction, virilization, Conn's and Cushing's syndrome myelolipomas are often found [1,3,4,11].

Macroscopically, the tumor usually appears as well-circumscribed, yellowish with red-brown areas intrapulmonary lesion [3,4]. Color depends on the amount of lipid component and hematopoietic elements [3]. Microscopically, myelolipomas are described as tumors composed of mature fatty tissue and hematopoietic tissue, including myeloid, erythroid, megakaryocytic cells, lymphocytes with possible finding of hemorrhage, bone segments, cartilage and calcifications in the tumor [8,9,11].

Bone tissue represents a questionable finding. Fowler et al. presented a case of myelolipoma without bony elements and consider unusual for them to be encountered in this tumor [2]. However, Sabate and Shahian, for example, reported a case of pulmonary myelolipoma containing bony structures [1]. Also, our case represents tumor with bony segments. So far, to the best of our knowledge, clinical significance of this debatable finding has not been determined.

Diagnosis of myelolipoma is established through performing imaging techniques (chest x-rays, CT scan, MRI) [3,9], but for final diagnosis establishment, pathohistological examination is required [7,11]. CT scan reveals myeloid parts of intrapulmonary myelolipoma to be higher in attenuation than adipose segment of the tumor [6], while on MRI, myeloid segments show low signal intensity and adipose tissue high intensity on T1-weighted imaging. Adipose tissue also demonstrates high signal intensity and myeloid parts intermediate signal intensity on T2-weighted imaging [7].

Differential diagnosis includes extramedullary hematopoiesis, hamartoma, lipoma, liposarcoma, phlebotangioma and teratoma. Extramedullary hematopoiesis rarely occurs in lungs, but in contrast to myelolipoma, it usually appears as multiple foci without

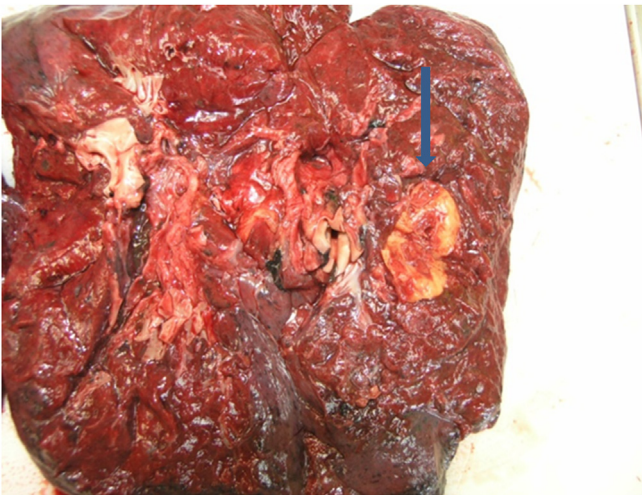


Fig. 1. Cut surface of the right lower lobe of the lung containing yellow-brown nodule 3 cm in size. (For interpretation of the references to colour in this figure legend, the reader is referred to the web version of this article.)

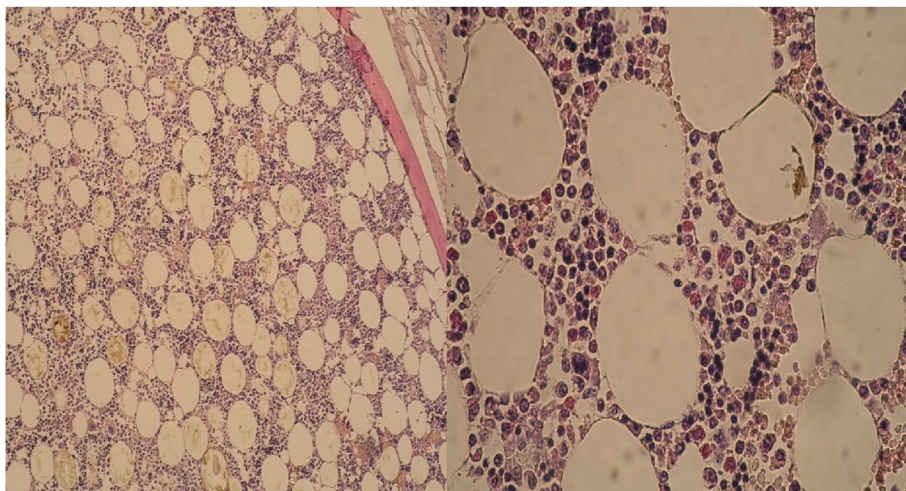


Fig. 2.1

Fig. 2.2

Fig. 2. H&E: 2.1 Well-demarcated lesion surrounded by bony spicules (H&E x 10 Magnification), **2.2** Tumor composed of mature adipose tissue and hematopoietic cells (myeloid cells, megakaryocytes, erythroid cells) (H&E x 40 Magnification).

well-circumscribed margins, it is mostly comprised of erythroid hyperplasia and hematopoietic elements, deprived of lymphoid tissue and contains small amount of fatty tissue [3,4,8]. It is usually related to other hematological conditions like anaemia or myeloproliferative conditions, which is not characteristic for myelolipoma [2,4,8,9]. Lipoma is benign tumor macroscopically characterized as well-defined, yellowish lesion histologically composed of mature fatty tissue. It is considered to be difficult to recognize in cases when myelolipoma contains mostly fat [7,8]. Liposarcoma is malignancy of adipose tissue, but unlike myelolipoma, usually demonstrates infiltrative growth [6]. Hamartoma is benign tumor, but more frequently observed than myelolipoma. Unlike to forementioned, it contains fatty tissue, fibromyxoid stroma, cartilage, bone and bronchial cells, without hematopoietic elements [7,8]. Teratomas are potentially malignant tumor composed of tissue originating from three germinal layers [7]. Xu et al. report that difficulty in distinguishing these two entities occurs when myelolipoma contains mostly hematopoietic cells. In those cases resolution lies in performing percutaneous needle biopsy [7]. Phlebotomy is considered to be uncommon lesion characteristic for abnormally ectopic venous vessels [12] that can be distinguished from myelolipoma by performing CT examination in order to reveal fatty tissue [7]. Myelolipomas should also be distinguished from metastasis, since cases with poorly demarcated and multiple lesions can occur and make establishing correct diagnosis difficult [4].

No surgical or other treatment of myelolipoma is required, however, in symptomatic patients and in cases of large lesions (larger than 7 cm) or ones with progressive growth, surgical removal is recommended [3,7].

4. Conclusion

Myelolipoma is a rare lesion that usually occurs in adrenal gland, while lungs and other sites represent less common finding. Although being a benign lesion and usually incidentally discovered, it is important to establish the diagnosis of myelolipoma, especially in cases of larger lesions with progressive growth [6,11], which can

cause tumor rupture and eventually life threatening hemorrhage or compression of adjacent structures, since those should be surgically removed [1,7,9]. Small asymptomatic lesions (less than 4 cm in size) should only be monitored [3,9]. Also, despite the fact that no cases of myelolipoma malignant transformation have been reported [8], distinguishing it from malignant lesions is necessary in order to adequately treat the patient [7].

Conflicts of interest

The authors declare that there is no conflict of interest regarding the publication of this paper.

References

- [1] C.J. Sabate, D.M. Shahian, Pulmonary myelolipoma, *Ann. Thorac. Surg.* 74 (2) (2002) 573–575.
- [2] K. Sato, Y. Ueda, S. Katsuda, K. Tsuchihara, Myelolipoma of the lung: a case report and brief review, *J. Clin. Pathol.* 60 (6) (2007) 728–730.
- [3] C. Shen, Z. Han, G. Che, A bilateral neoplasm in chest: a case report and literature review, *Bmc. Surg.* 14 (2014) 42–48.
- [4] S.B. Hunter, E.H. Schemankewitz, C. Patterson, V.A. Varma, Extraadrenal myelolipoma. A report of two cases, *Am. J. Clin. Pathol.* 97 (3) (1992) 402–404.
- [5] J. Wen, H. Chen, W. Yi, X. Zhou, Primary costal myelolipoma: a case report and review of the literature, *Int. J. Clin. Exp. Pathol.* 8 (2) (2015) 2202–2204.
- [6] A. Hakim, C. Rozeik, Adrenal and Extra-adrenal Myelolipomas - a comparative case report, *J. Radiol. Case. Rep.* 8 (2014) 1–12.
- [7] Q. Xu, X. Yin, W. Huang, J. Sun, X. Wu, L. Lu, Intrapulmonary myelolipoma and its computed tomography features: a case report and literature review, *Oncol. Lett.* 9 (2015) 1677–1680.
- [8] W. Huang, Y. Zhao, X. Yin, Q. Qi, Primary myelolipoma of the lung: a case of report and review of literature, *Pol. J. Pathol. Off. J. Pol. Soc. Pathol.* 63 (3) (2012) 204–206.
- [9] L. Fournel, A. Mansuet-Lupo, M.P. Revel, J.F. Régnard, Thoracic myelolipoma: a rare case of mistake in lung cancer staging, *J. Clin. Exp. Pathol.* 5 (2014) 1–2.
- [10] W.T. Huang, S.J. Zhao, D.M. Lin, Pulmonary-bronchus myelolipoma and review on extra-adrenal myelolipomas in Chinese literature, *Chin. Med. J.* 125 (17) (2012) 3188–3190.
- [11] M. Bezjak, P. Sesar, M. Ulamec, I. Pavić, A. Mijić, B. Spajić, B. Kruslin, Adrenal myelolipoma-report of 15 patients, *Acta. Med. Croat. Cas. Hrvatske Akad. Med. Znan.* 67 (3) (2013) 255–258.
- [12] S. Hernández-Castro, E. Navarrete-García, A. López-Alarcón, E. Torres-Medina, A. Peña-Rodríguez, G. Rosales-Rocha, Giant genital phlebotomy: autologous graft repair, *Rev. Mex. Urol.* 70 (2010) 308–311.