

Dedifferentiated Primary Parosteal Osteosarcoma of the Temporal Bone in a 19-Year-Old Patient: A Case Report

Košec, Andro; Šarić, Domagoj; Čupić, Hrvoje; Ajduk, Jakov

Source / Izvornik: **The Journal of International Advanced Otology, 2023, 19, 431 - 434**

Journal article, Published version

Rad u časopisu, Objavljena verzija rada (izdavačev PDF)

<https://doi.org/10.5152/iao.2023.22923>

Permanent link / Trajna poveznica: <https://um.nsk.hr/um:nbn:hr:105:306833>

Rights / Prava: [Attribution-NonCommercial 4.0 International](#)/[Imenovanje-Nekomercijalno 4.0 međunarodna](#)

Download date / Datum preuzimanja: **2024-12-27**



Repository / Repozitorij:

[Dr Med - University of Zagreb School of Medicine Digital Repository](#)



Case Report

Dedifferentiated Primary Parosteal Osteosarcoma of the Temporal Bone in a 19-Year-Old Patient: A Case Report

Andro Košec^{1,2} , Domagoj Šarić² , Hrvoje Čupić^{2,3} , Jakov Ajduk^{1,2} 

¹Department of Otorhinolaryngology and Head and Neck Surgery, University Hospital Center Sestre Milosrdnice, Zagreb, Croatia

²University of Zagreb, School of Medicine, Zagreb, Croatia

³Department of Pathology "Ljudevit Jurak," University Hospital Center Sestre Milosrdnice, Zagreb, Croatia

ORCID iDs of the authors: A.K. 0000-0001-7864-2060, D.Š. 0000-0001-6309-0419, H.Č. 0000-0003-2235-4515, J.A. 0000-0003-3648-0280.

Cite this article as: Košec A, Šarić D, Čupić H, Ajduk J. Dedifferentiated primary parosteal osteosarcoma of the temporal bone in a 19-year-old patient: A case report. *J Int Adv Otol.* 2023;19(5):431-434.

Osteosarcoma is the most common primary malignant tumor affecting the bone but is a rare occurrence in the head and neck region. Complete surgical resection with wide surgical margins is currently the main treatment strategy for osteosarcoma but can be hard to achieve due to the complex anatomy of the head and neck. We report the first case of primary high-grade dedifferentiated parosteal osteosarcoma arising from the temporal bone in published literature. The 19-year-old patient presented with a left retroauricular lesion measuring 3 cm in diameter. Radiographic imaging and biopsy suggested the diagnosis of intermediate-grade chondrosarcoma, but definitive histopathology confirmed a diagnosis of dedifferentiated parosteal osteosarcoma. The tumor was resected with wide margins, removing the underlying temporal bone, periosteum and overlying soft tissue through a lateral temporal bone resection. The middle ear was reconstructed with cartilage grafting, and the dura of the posterior and middle cranial fossa was covered using temporal fascia grafts and local transpositional flaps. The patient is recurrence free 10 months after treatment. This report was assembled following CARE [The CARE guidelines (for Case Reports)] guidelines and describes clinical, histological, and radiological manifestations of our patient's rare clinical entity and may provide more data in treating patients with osteosarcoma affecting the anatomically complex head-and-neck region.

KEYWORDS: Temporal bone, osteosarcoma, parosteal dedifferentiated, surgery, case report

INTRODUCTION

Osteosarcoma (OS) is the most common primary malignant tumor of the bone, originating from mesenchymal stem cells. It commonly affects long bones in young adults and children, with an incidence of 1:100 000 per year.¹ Only 6%-10% of OS are found in the head and neck region, predominantly occurring in the maxilla, mandible, and zygomatic bones.^{1,2} With the skull being affected in 1% of cases, primary OS of the temporal bone is quite rare. We present a case of a 19-year-old male patient with primary dedifferentiated parosteal OS of the temporal bone, an entity associated exclusively with disease recurrence rather than a primary lesion. The unique localization, treatment details, and histopathologic data are relevant in expanding the current level of knowledge on the subject.

CASE PRESENTATION

A 19-year-old male patient reported an enlarging left retroauricular bony lesion, which he had first noticed 5 months earlier. There was no history of pain, trauma, hearing loss, tinnitus, or otorrhea. He was examined in another institution 2 months earlier, and a computed tomography (CT) scan of the temporal bone and magnetic resonance imaging (MRI) of the brain were recommended. He was otherwise in good health and taking no medication. On physical examination, the lesion was approximately 3 cm wide in diameter, painless, and attached to the underlying bone on palpation. Otoscope findings were normal.

Left temporal bone CT revealed a hyperostotic lesion of the mastoid process measuring 38 × 10 mm, with an extension to the posterior aspect of the external auditory meatus (EAM) measuring 9 × 9 mm (Figure 1). No osteolytic changes were described.

Corresponding author: Andro Košec, e-mail: andro.kosec@yahoo.com

Received: August 29, 2022 • Accepted: March 23, 2023 • Publication Date: September 29, 2023

Available online at www.advancedotology.org



Content of this journal is licensed under a
Creative Commons Attribution-NonCommercial
4.0 International License.

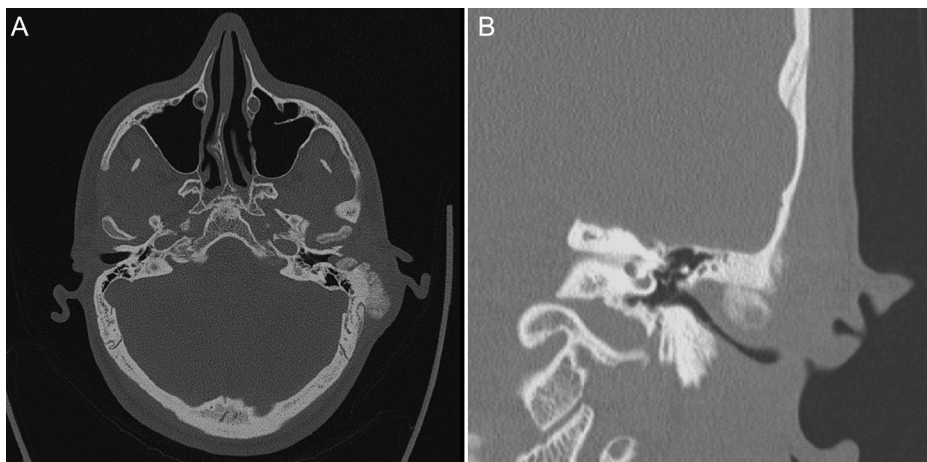


Figure 1. Preoperative computed tomography scan of the left temporal bone. (A) Axial view showing a hyperostotic exophytic lesion, measuring up to 3 cm in diameter. (B) Coronal view showing posterior external auditory meatus infiltration and no tumor in the tympanic cavity.

The tympanic cavity was normal. Contrast-enhanced temporal bone MRI showed a left-sided expansive mass originating from the external cortex and periosteum of the squamous part of the temporal bone, expanding into the posterior part of EAM. Its dimensions were 50 mm in the cephalo-caudal (CC) plane and 40 mm in the antero-posterior (AP) plane. The post-contrast scan revealed the mass to be intense, heterogeneous, indicative of chondrosarcoma, or parosteal OS (Figure 2).

A multidisciplinary oncology team recommended surgical treatment with an open biopsy prior to surgery to obtain a definitive diagnosis. Biopsy samples were made up of mixed chondroid and osseous tumor tissue, moderately to focally cellular, and consisted of atypical, partially binuclear, and multinuclear chondrocytes within a chondroid matrix. These cells showed moderate anisokaryosis and hyperchromasia, with up to 1 mitosis/30 high-power fields. Histopathological findings were indicative of a diagnosis of well-to-moderately differentiated chondrosarcoma, grade 1/2. However, additional immunostaining and MDM2 amplification coupled with radiographic characteristics of the tumor confirmed parosteal dedifferentiated OS.

The curative surgical procedure was performed under general anesthesia. An exophytic tumor mass arising from the mastoid cortex was observed, spreading superficially on the squamous part of the temporal bone and toward the occipital suture and anteriorly reaching the zygomatic root and the anterior EAM (Figure 3). An extended postauricular access was performed, and the skin flap was elevated. The surgical area where the biopsy was performed was resected, and the temporal muscle, periosteum, and soft tissue surrounding the tumor were removed. A circular craniotomy of the squamous part of the temporal bone through the temporo-occipital suture was performed, and the dura was detached from the bone. The tumor and surrounding bone were removed with wide margins, exposing the sigmoid sinus, comprising a lateral temporal bone resection, with the removal of the ossicles after separating the incudo-stapedial joint, Eustachian tube closure, and an extended posterior tympanotomy. The bony external auditory canal was resected *en bloc* through an anterior osteotomy detaching the zygomatic process and preserving the synovial capsule of the temporomandibular joint.

Mastoid apex amputation followed, with resection margins reaching the jugular bulb medially, the parotid segment of the facial nerve,

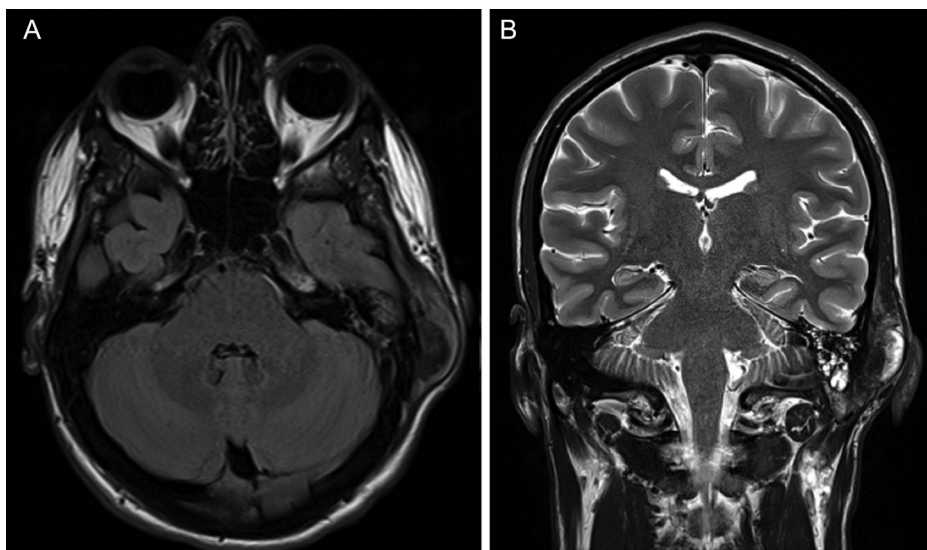


Figure 2. Preoperative magnetic resonance imaging. (A) Axial T1-weighted image showing the temporal bone lesion with heterogeneous signal intensity. (B) Coronal T2-weighted image showing the tumor cephalo-caudal extension up to 50 mm.

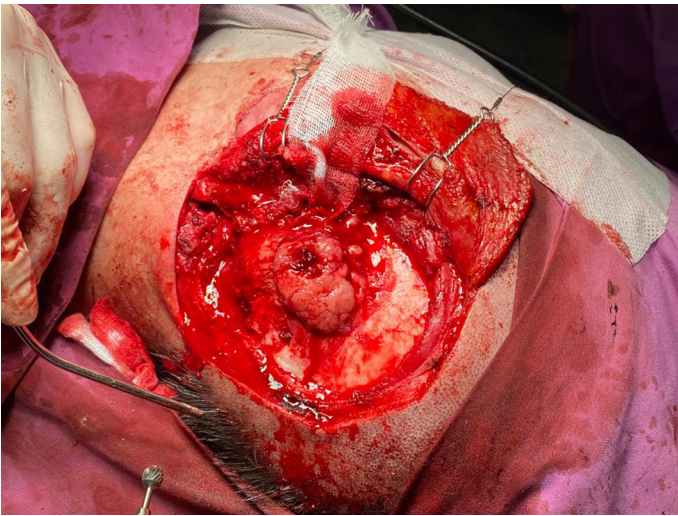


Figure 3. Intraoperative photograph of the tumor and surrounding bone after soft tissue removal.

and the TMJ capsule anteriorly. Reconstruction of the postablative defect included middle ear cartilage grafting, while the dura of the posterior and middle cranial fossa was covered using temporal fascia grafts and local transpositional flaps (Figure 4).

Ex tempore biopsy of tumor margins revealed an inferior margin toward the mastoid apex to be infiltrated with tumor tissue of similar histologic features to samples retrieved during the probatory biopsy.

Postoperative microscopic analysis of decalcified osseous tumor tissue revealed spindle-cell clusters with marked hyperchromasia and anisokaryosis, significant mitotic activity (9 mitosis/10 hpf), osteoid deposition, and osseous trabeculae formation. Some samples contained parts with chondroid differentiation. Parts of mature bone infiltrated with tumors were also found. Soft-tissue tumor mass was of moderate to high cellularity and consisted of a chondroid matrix

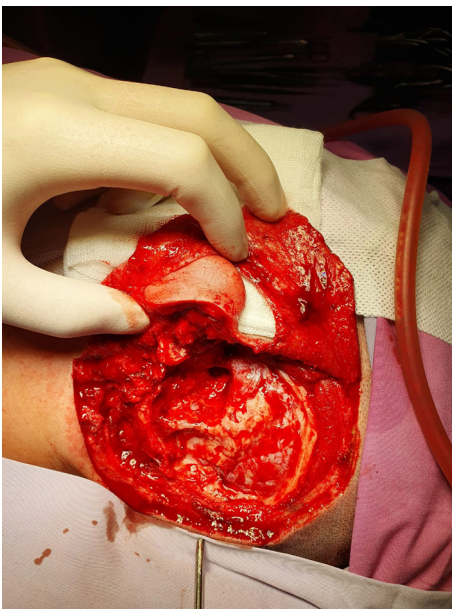


Figure 4. Surgical deficit after complete resection of the tumor through lateral temporal bone resection.

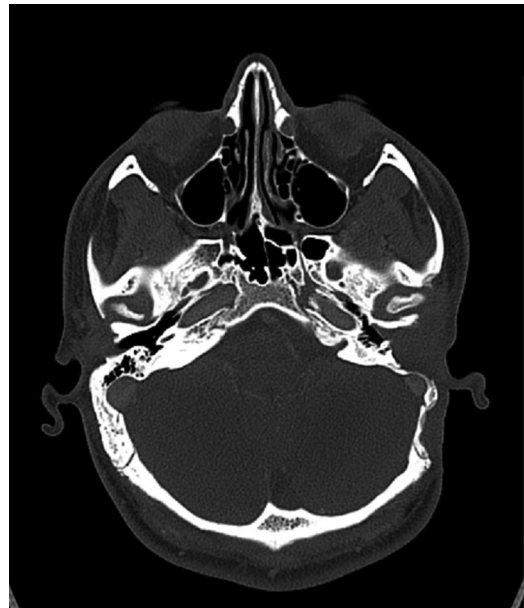

Figure 5. Follow-up temporal bone computed tomography scan obtained 3 months postoperatively, showing no signs of disease recurrence.

with atypical, partially binuclear, and multinuclear chondrocytes, which exhibited moderate anisokaryosis and hyperchromasia. Many irregular calcifications were also present. Although the histopathologic characteristics of the initial biopsy were suggestive of chondrosarcoma, histological and radiological correlation yielded the final diagnosis of high-grade parosteal OS with dedifferentiation, infiltrating the surrounding bone and leading to clear surgical margins.

After a chest, abdomen, and inguinal CT showed no signs of hematogenous metastases, the patient was further treated with postoperative chemotherapy, following the protocol for parosteal OS. No tumor recurrence was present on follow-up CT scans obtained 3 months after surgery, and the patient is disease-free 10 months after surgery (Figure 5). Written informed consent from the patient was obtained allowing the publication of relevant medical data according to ethical standards of good clinical practice.

DISCUSSION

Aggressive OS types typically affect patients in their 2nd-4th decades of life.³⁻⁵ Although some etiological factors are known to increase the risk of OS, such as previous irradiation, benign bone disorders, and trauma, none of these were identified in our patient.^{1,3,4}

In the craniofacial region, common symptoms include a painful or painless, slowly growing lump, headache, and cranial nerve dysfunction.⁶⁻⁸ Differential diagnoses include not only benign lesions such as osteoma, osteochondroma, myositis ossificans, and fibrous dysplasia but also malignant tumors of epithelial, salivary, mesenchymal, or unknown origin. Villemure-Poliquin et al not only reported 5-year overall survival of more than 90% for low-grade surface OS but also accentuated their ability to dedifferentiate into the high-grade surface OS, exhibiting aggressive clinical behavior similar to conventional intramedullary OS.⁹ Histologically, as was the case in our patient, peripheral malignant chondroid areas and anaplastic spindle cells, as well as fine osteoid production, are present. Osteosarcoma tends to give hematogenous metastases,

most frequently occurring in the lungs, lymph nodes, liver, and brain.³ Dedifferentiated parosteal OS is usually reported to emerge after multiple operations and recurrences of a previous parosteal OS, with subsequent metastases and an adverse prognosis.⁵ It is extremely rare to manifest as a primary lesion in the temporal bone, which was the case in our patient.

Plain x-ray and CT images usually depict parosteal OS as an exophytic juxtacortical mass. Bone density tends to be lower on the periphery compared to the center of the tumor.⁹ Osteosarcoma may present as an osteolytic lesion, appearing radiolucent, or an osteoblastic lesion, appearing sclerotic, or as a combination of both.¹⁰ Aggressive periosteal reactions, “sunburst appearance,” are frequently encountered on radiologic images of high-grade lesions but weren’t observed on our patient’s scans. The “string sign,” a radiolucent line separating the cortical bone adjacent to the tumor, is visible in up to 30% of cases on plain x-ray and 65% of cases on the CT scan but wasn’t obvious in our case.^{5,9} On MRI, bony parts of the tumor tend to be hypointense on both T1- and T2-weighted images, whereas soft tissues can be heterogeneous and are enhanced with contrast, which was the case in our patient.

Along with features of conventional POS—sarcomatous stroma with malignant spindle cells producing neoplastic osteoid tissue or bony trabeculae—dedifferentiated POS has foci of high-grade OS.³ Features of high-grade OS include tumor cells with marked hyperchromasia, anisokaryosis, significant mitotic activity, disorganized and irregularly distributed osteoid, and irregular bony trabeculae.⁸ These features were present in the postsurgical histological analysis of the tumorous tissue of our patient, alongside areas of chondroid differentiation, implying dedifferentiation of neoplastic osteoblasts into atypical chondrocytes. The presence of foci of high-grade OS is regarded to be the most important prognostic factor.⁵ Positive *GNAS* mutation is associated with fibrous dysplasia and is useful in differential diagnosis. Also, 2 genes are usually amplified in parosteal OS: *MDM2* and *CDK4*, with at least one of these mutations being positive in 87-100% of cases.⁹ However, negative staining does not exclude the diagnosis.

In general, a multimodal treatment plan including surgery, radiotherapy, and chemotherapy is favored for patients with OS. Complete surgical resection with negative margins wider than 1 cm is the most important prognostic factor, which makes it the treatment of choice for low-grade surface OS. Head and neck OS is associated with higher mortality. Due to the complex anatomy of the region, wide surgical margins can be hard to achieve, making the likelihood of local recurrence and/or dedifferentiation into high-grade lesions quite high.^{2,9} In our case, muscles, soft tissue surrounding the tumor, and the periosteum were removed. The tumor and surrounding bone were resected through a wide lateral temporal bone resection. Current multimodal treatment strategies enable approximately 75% of all patients with OS to be cured. According to Funakoshi et al, radiotherapy improves overall survival and local control of tumors for patients with head and neck OS when only partial excision can be

achieved, but in our patient, surgical margins were negative, prompting chemoradiotherapy.²

CONCLUSION

To the best of our knowledge, this is the first case of dedifferentiated POS occurring at this localization as a primary lesion. The correlation between clinical presentation and histological and radiological findings has proven to be crucial in deciding on the optimal therapeutic approach. The surgical details described in this case may provide more data on surgical strategies for rare OS occurring in anatomically complex craniofacial areas.

Informed Consent: Written informed consent was obtained from the patient who agreed to take part in the study.

Peer-review: Externally peer-reviewed.

Author Contributions: Concept – A.K., D.Š., J.A., H.Č.; Design – A.K., D.Š., J.A., H.Č.; Supervision – A.K., D.Š., J.A., H.Č.; Resources – A.K., D.Š., J.A., H.Č.; Materials – A.K., D.Š., J.A., H.Č.; Data Collection and/or Processing – A.K., D.Š., J.A., H.Č.; Analysis and/or Interpretation – A.K., D.Š., J.A., H.Č.; Literature Search – A.K., D.Š., J.A., H.Č.; Writing – A.K., D.Š., J.A., H.Č.; Critical Review – A.K., D.Š., J.A., H.Č.

Declaration of Interests: The authors have no conflict of interest to declare.

Funding: The authors declared that this study has received no financial support.

REFERENCES

1. Brusić SK, Pusić M, Cvjetković N, et al. Osteosarcoma of the mastoid process following radiation therapy of mucoepidermoid carcinoma of the parotid gland - a case report. *Coll Antropol.* 2012;36(suppl 2):223-225.
2. Funakoshi Y, Shono T, Kurogi A, Kono S. Osteosarcoma of the temporal bone occurring 40 years after radiotherapy: a technical case report presenting en bloc resection of intra- and extracranial lesions followed by a one-stage reconstruction. *Surg Neurol Int.* 2021;12:152. [\[CrossRef\]](#)
3. Gertner R, Podoshin L, Fradis M. Osteogenic sarcoma of the temporal bone. *J Laryngol Otol.* 1983;97(7):627-631. [\[CrossRef\]](#)
4. Hsieh ST, Guo YC, Tsai TL, Li WY, Lin CZ. Parosteal osteosarcoma of the mastoid bone following radiotherapy for nasopharyngeal carcinoma. *J Chin Med Assoc.* 2004;67(6):314-316.
5. Iemoto Y, Ushigome S, Ikegami M, Koide K. Case report 648: parosteal osteosarcoma arising from the right temporal bone. *Skeletal Radiol.* 1991;20(1):59-61. [\[CrossRef\]](#)
6. Marioni G, Mazzoni A, Zanoletti E. Histopathology-related pitfalls in temporal bone malignancy prognostics. *Auris Nasus Larynx.* 2019;46(6):958-959. [\[CrossRef\]](#)
7. Sanal HT, Kilickesmez O, Can C. Radiology quiz case 2. Classic osteosarcoma of the temporal bone. *Arch Otolaryngol Head Neck Surg.* 2005;131(10):922, 926. [\[CrossRef\]](#)
8. Sharma SC, Handa KK, Panda N, Banerjee AK, Mann SB. Osteogenic sarcoma of the temporal bone. *Am J Otolaryngol.* 1997;18(3):220-223. [\[CrossRef\]](#)
9. Villemure-Poliquin N, Trudel M, Labonté S, Blouin V, Fradet G. Low-grade surface osteosarcoma of the temporal bone in paediatric patients: a case report and literature review. *Clin Med Insights Pediatr.* 2019;13:1179556519855381. [\[CrossRef\]](#)